

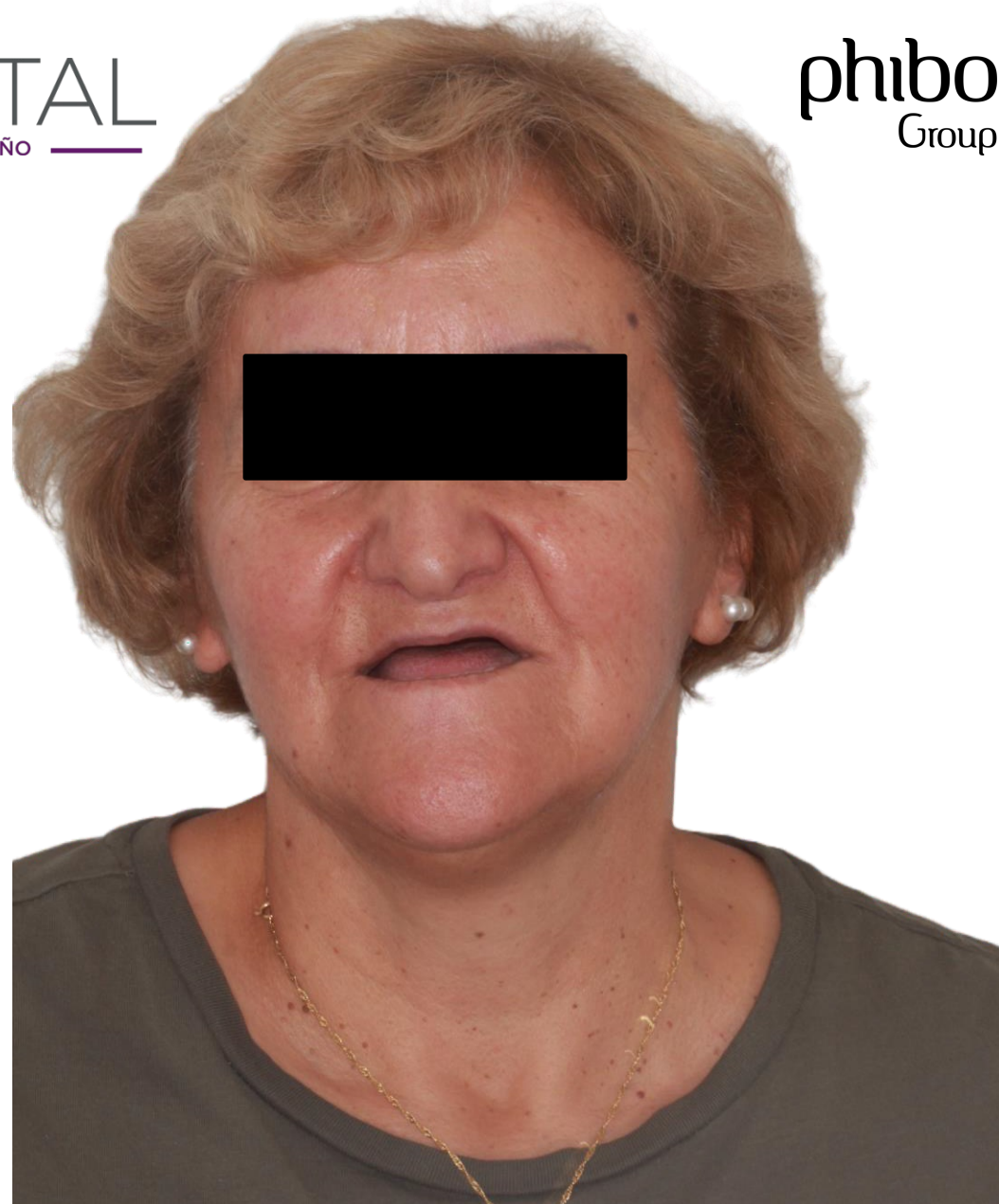

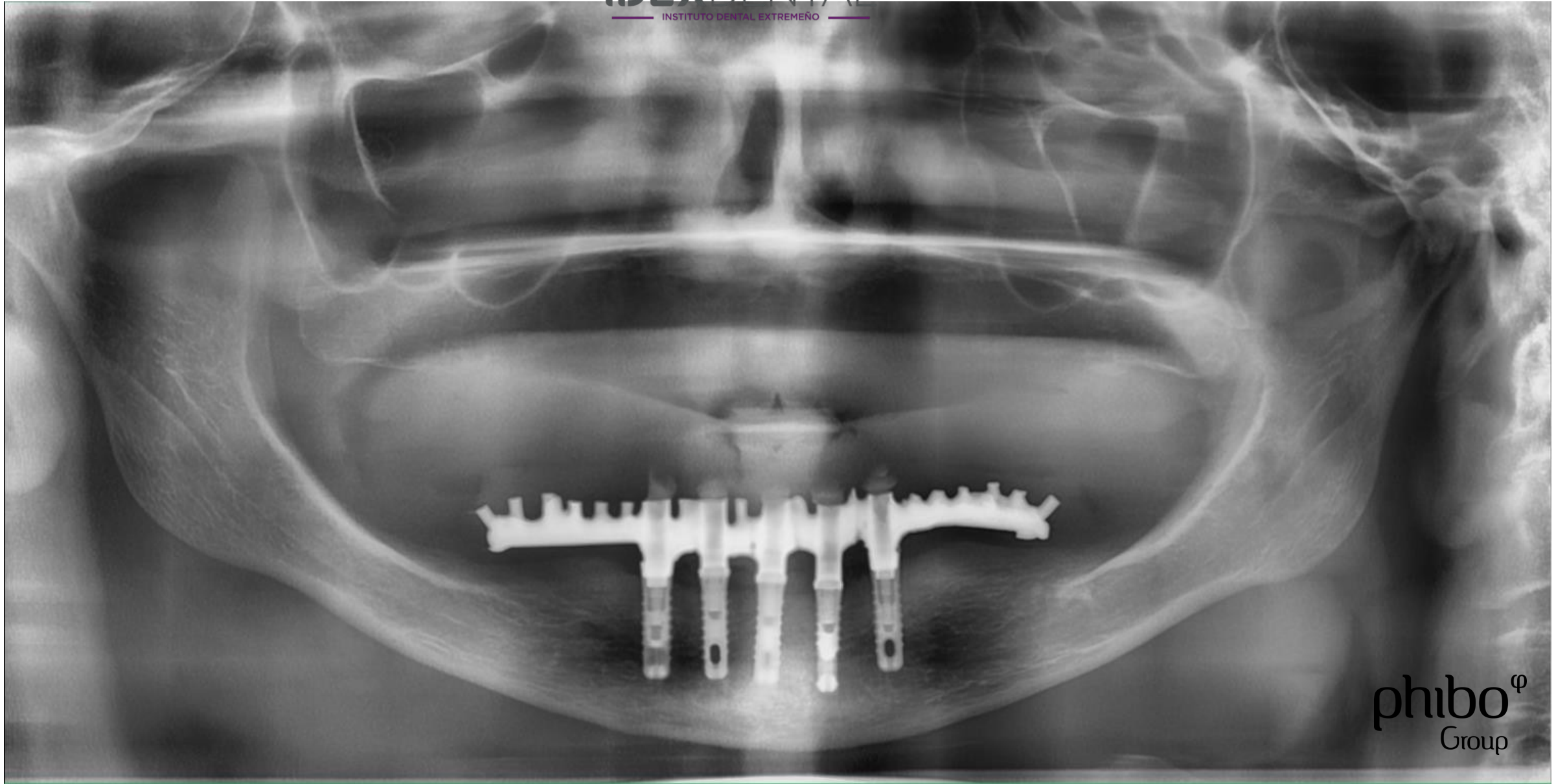*Dr. Jesús García De Blas
y Dra. María Sánchez*

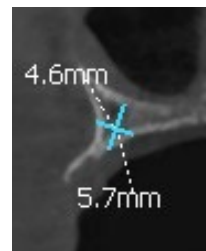
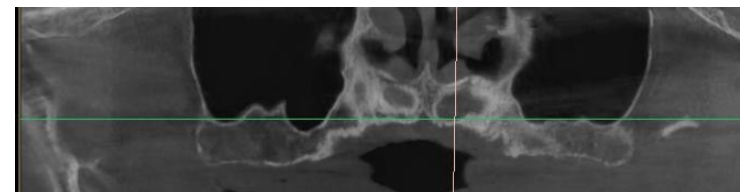
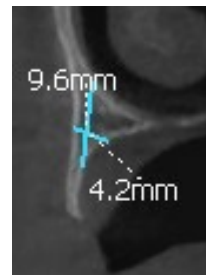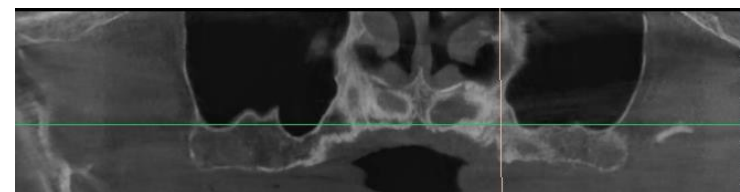
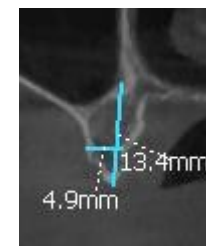
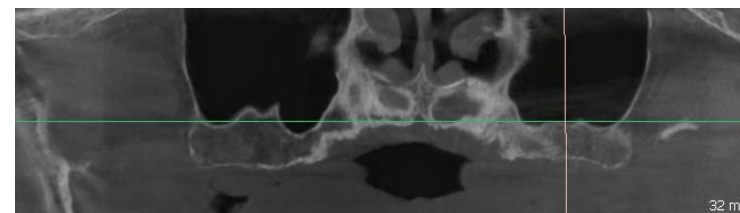
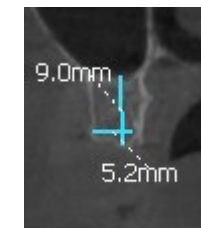
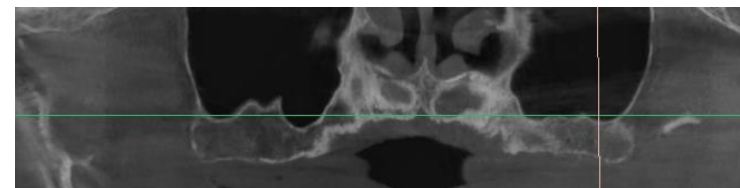

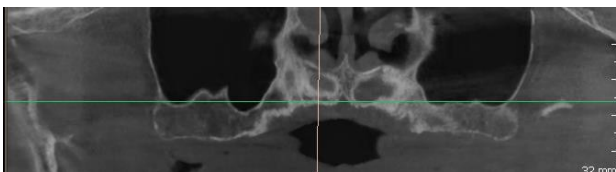
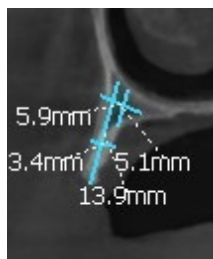
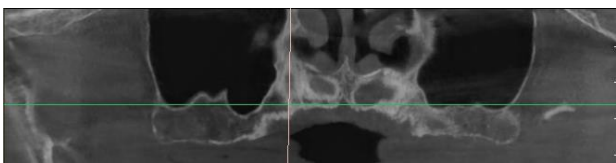

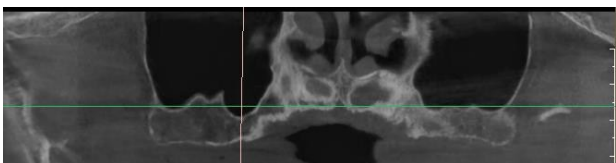
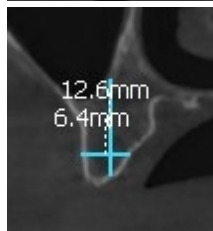
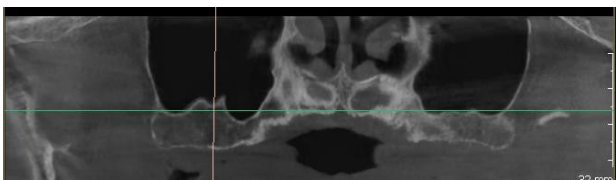
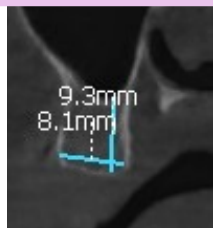
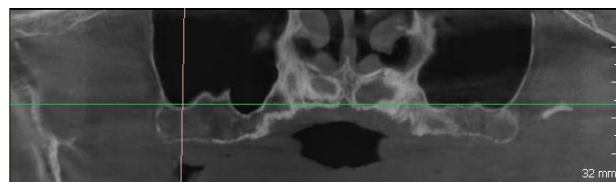
- *Paciente Femenina
- *Gran pérdida de dimensión vertical y soporte labial.
- *Maxilar con gran reabsorción ósea y en filo de cuchillo.
- *Plan de tratamiento:
Rehabilitación completa superior sobre implantes TSH by Phibo

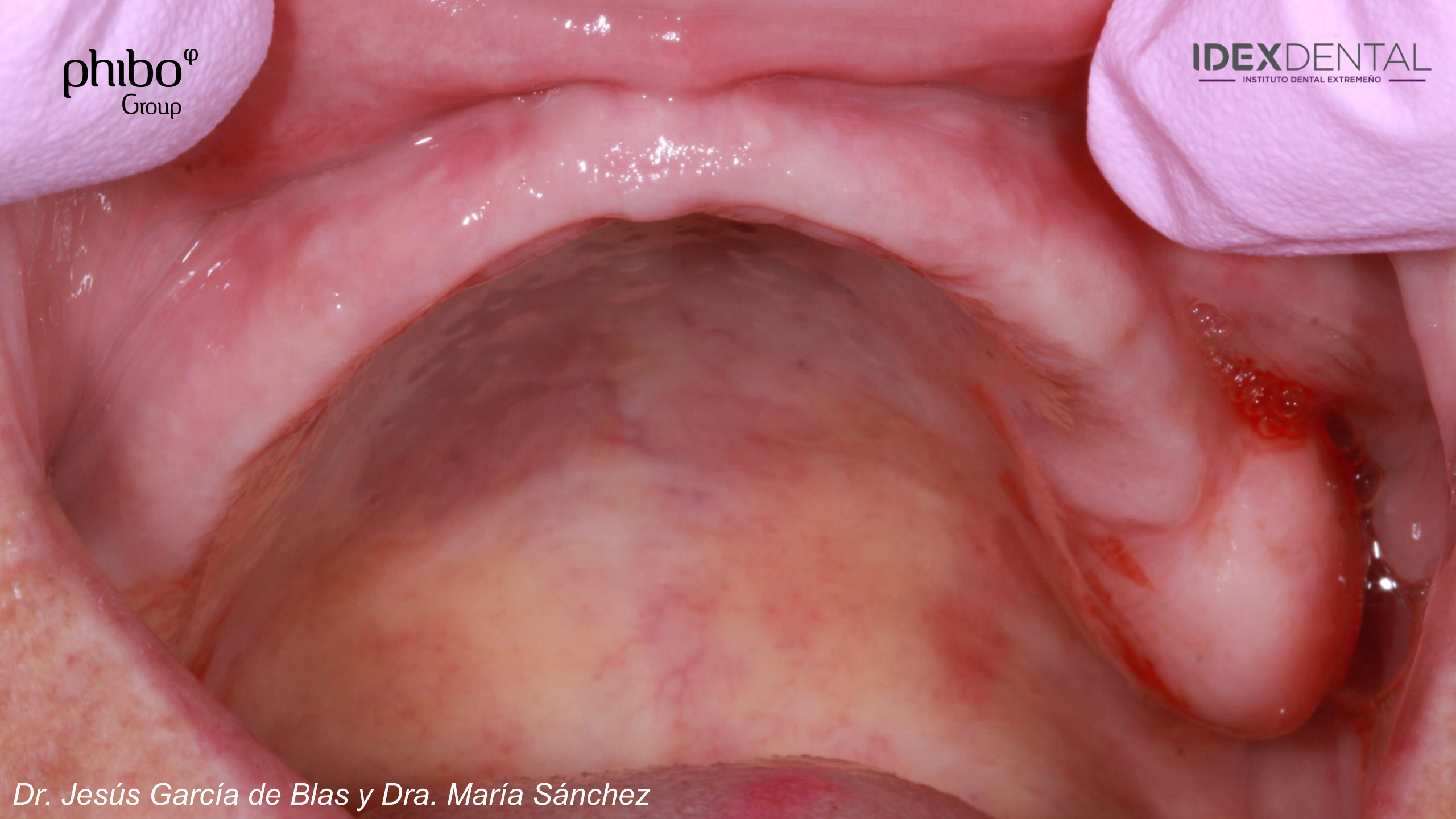Dr. Jesús García de Blas y
Dra. María Sánchez

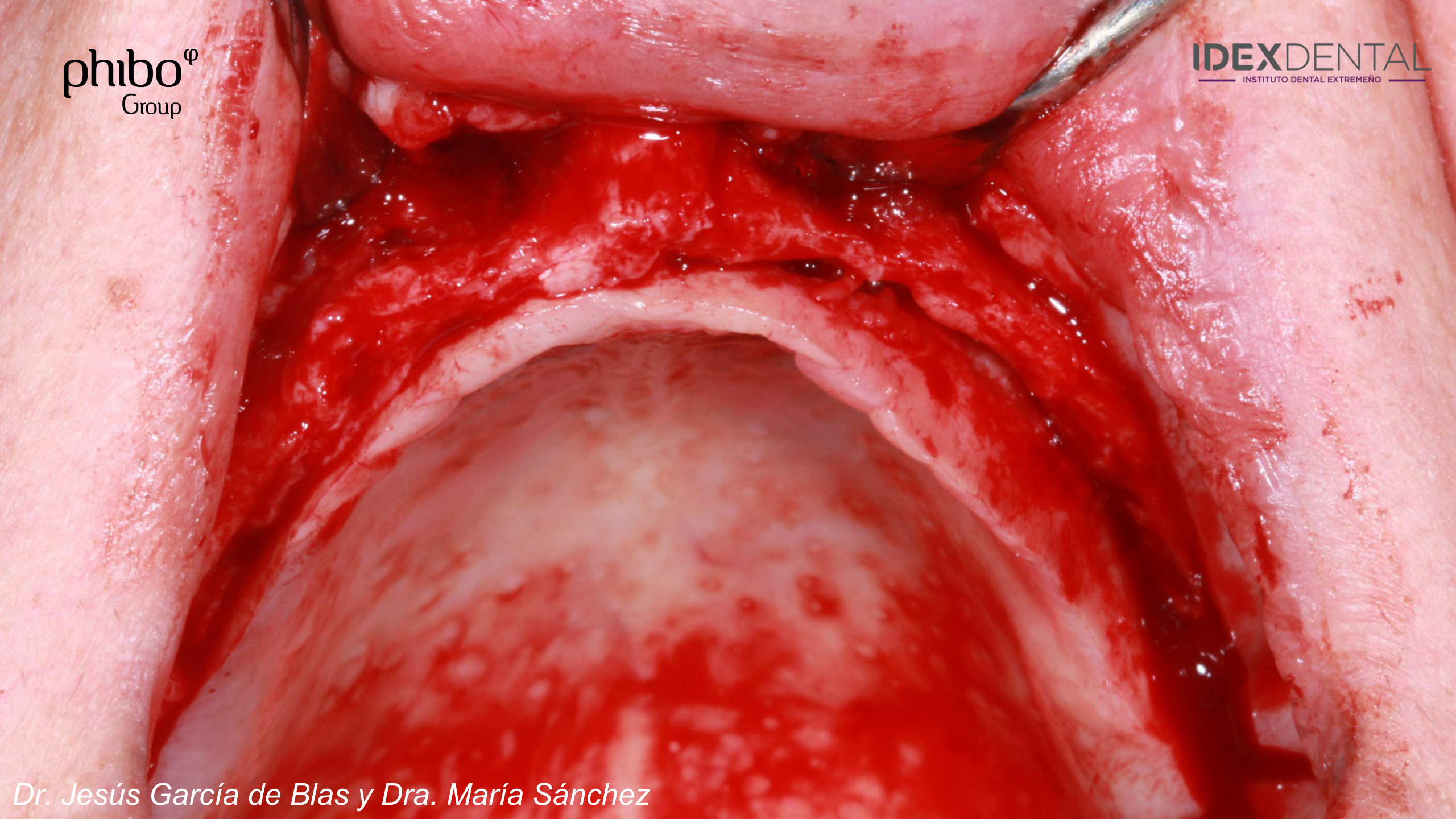

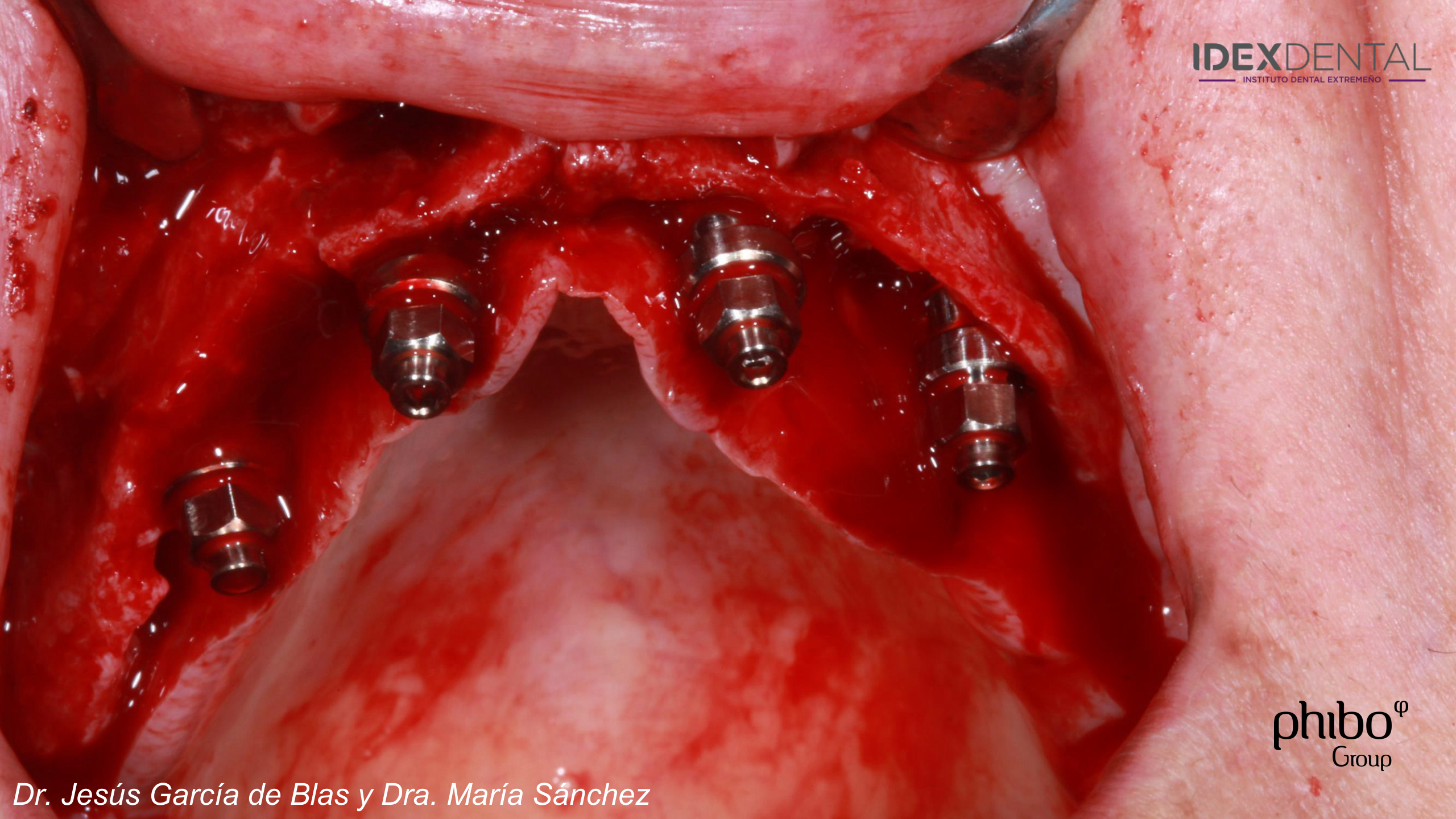


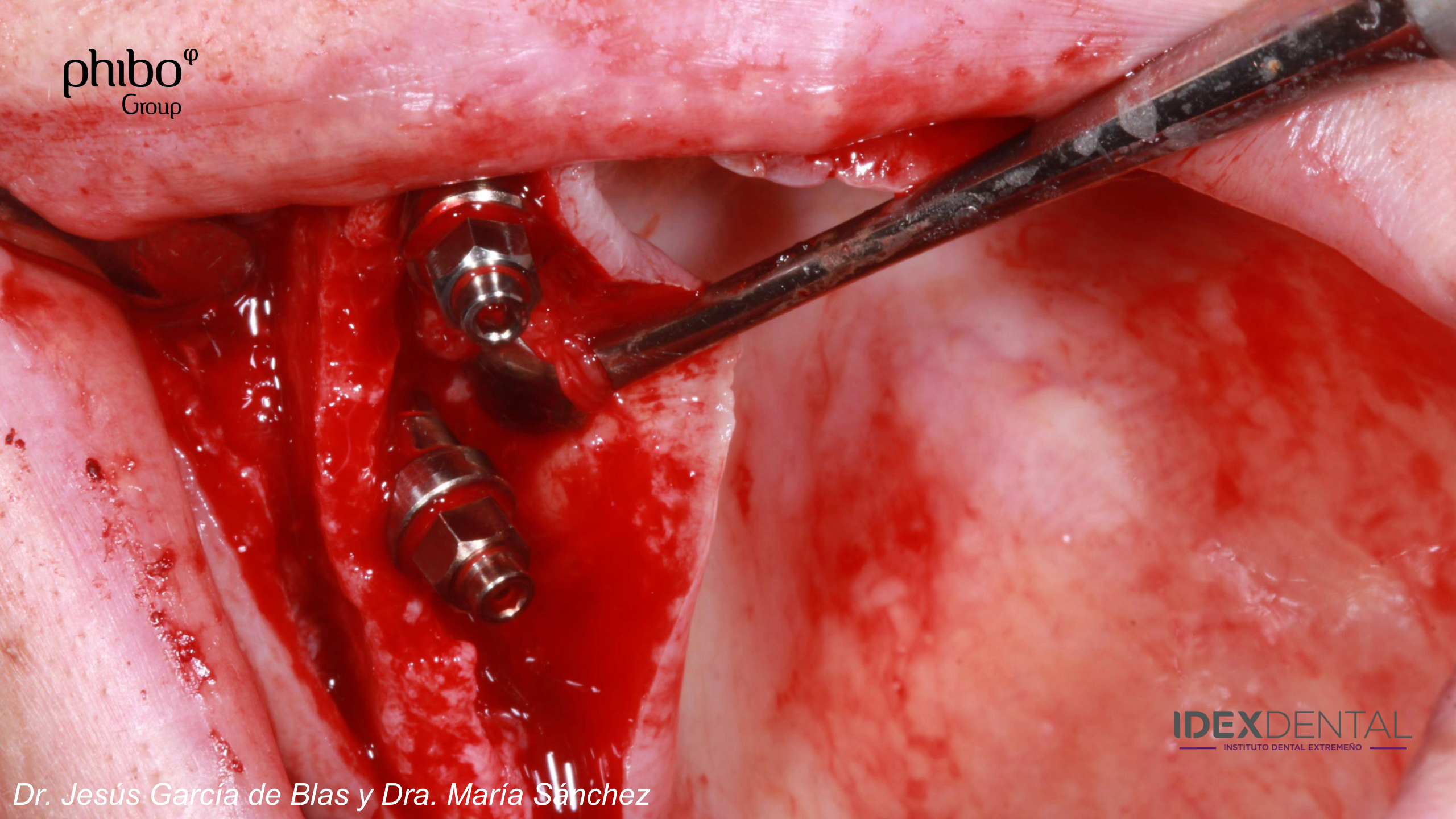


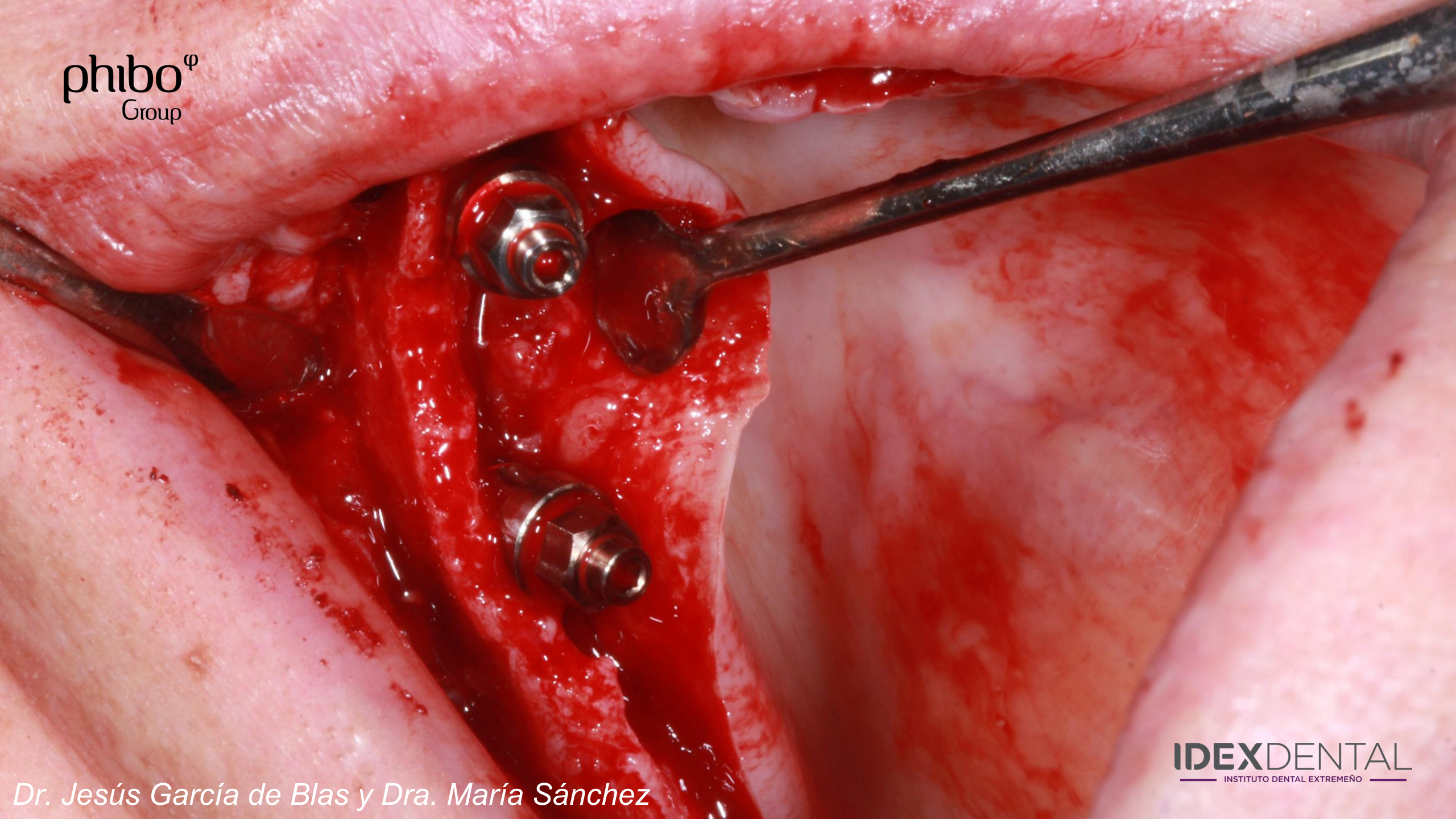


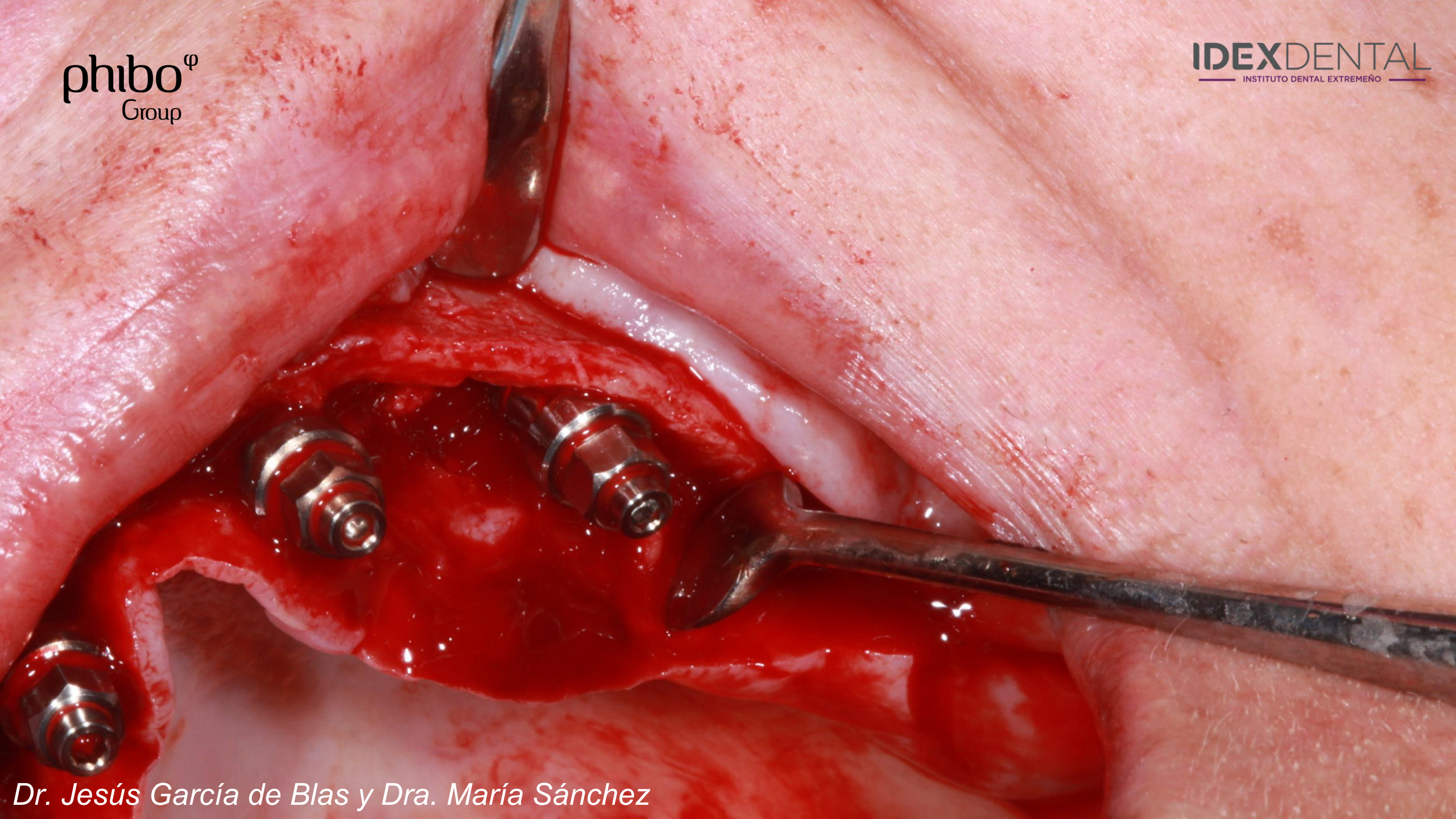


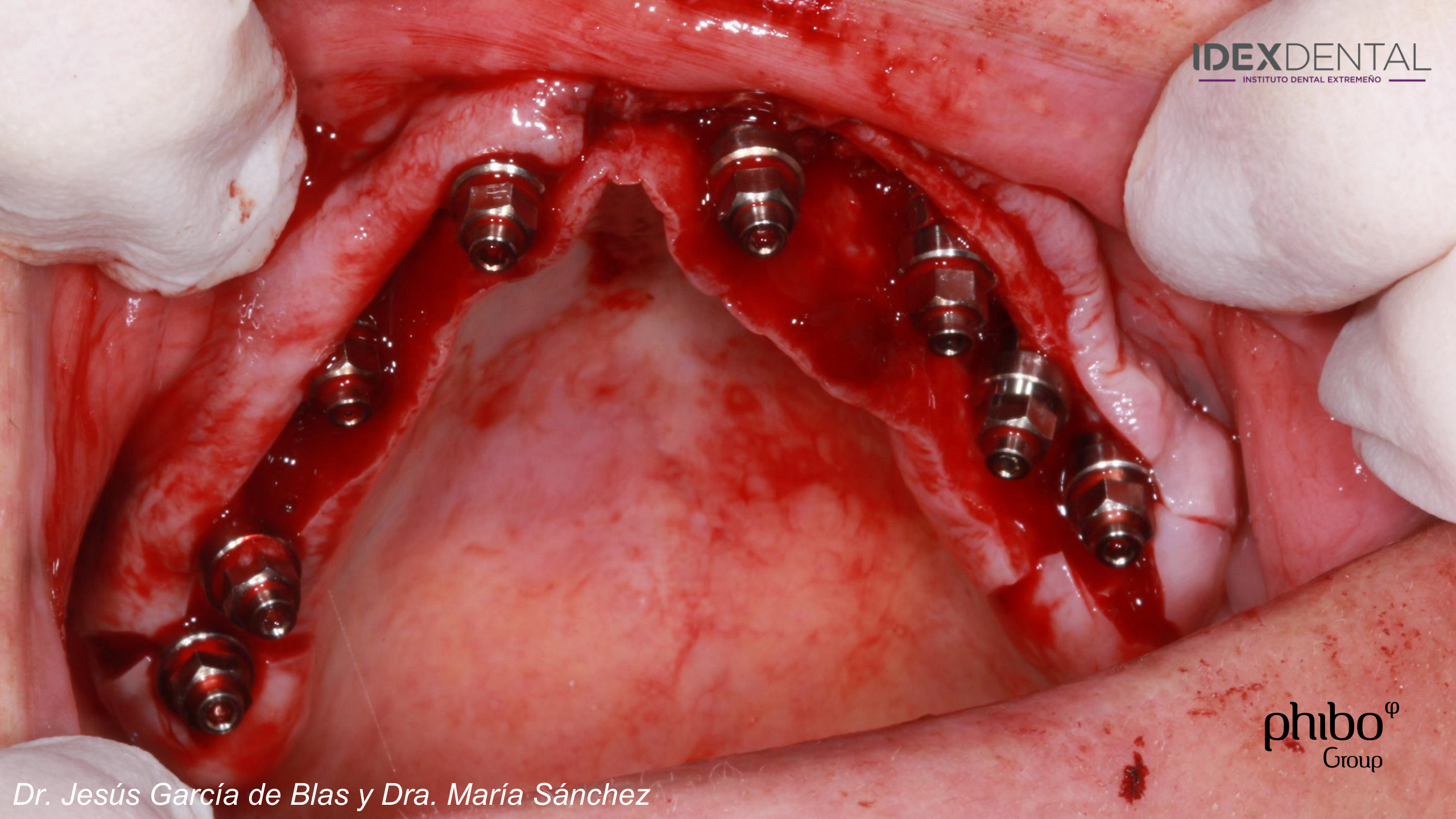


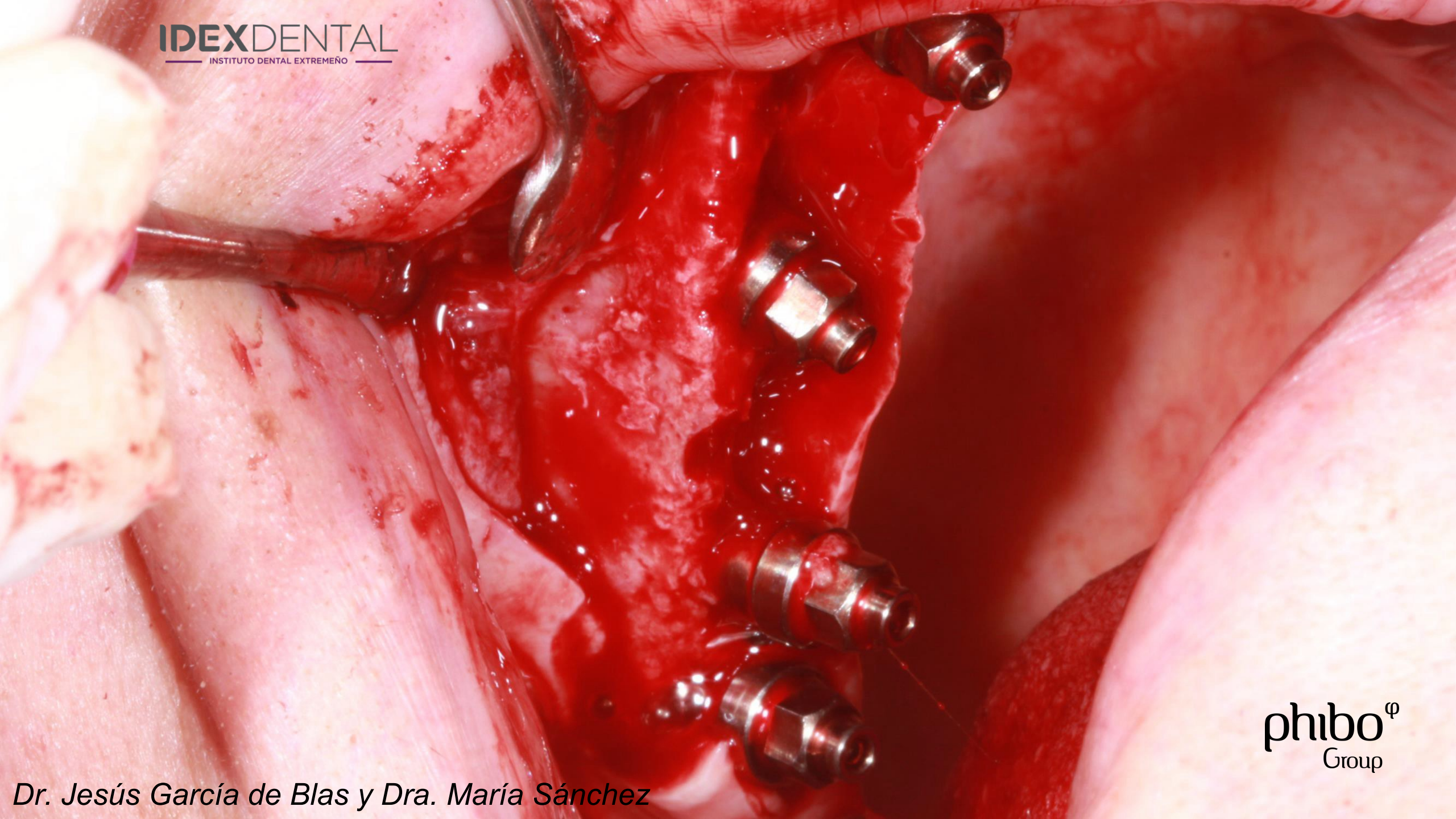


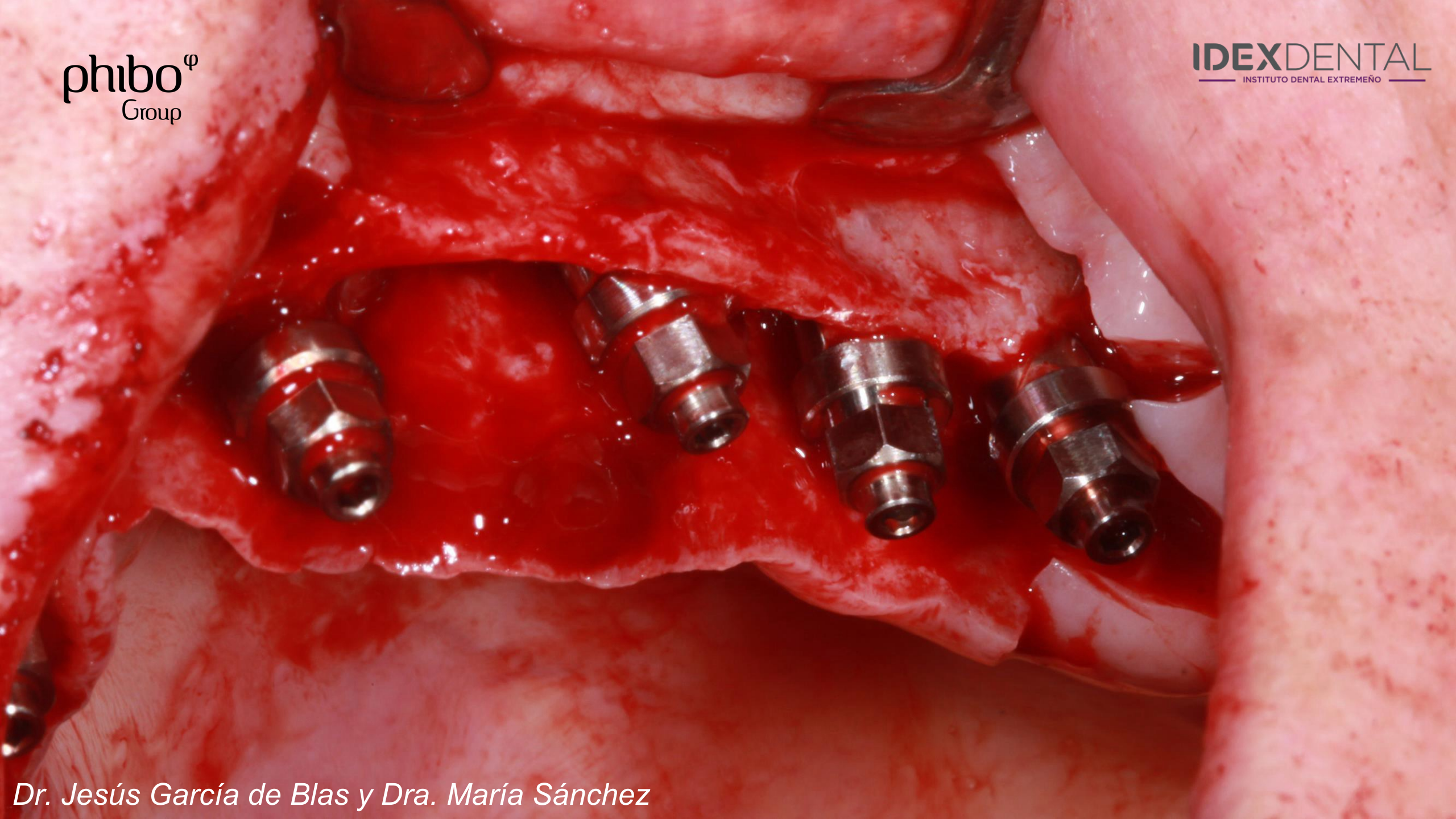


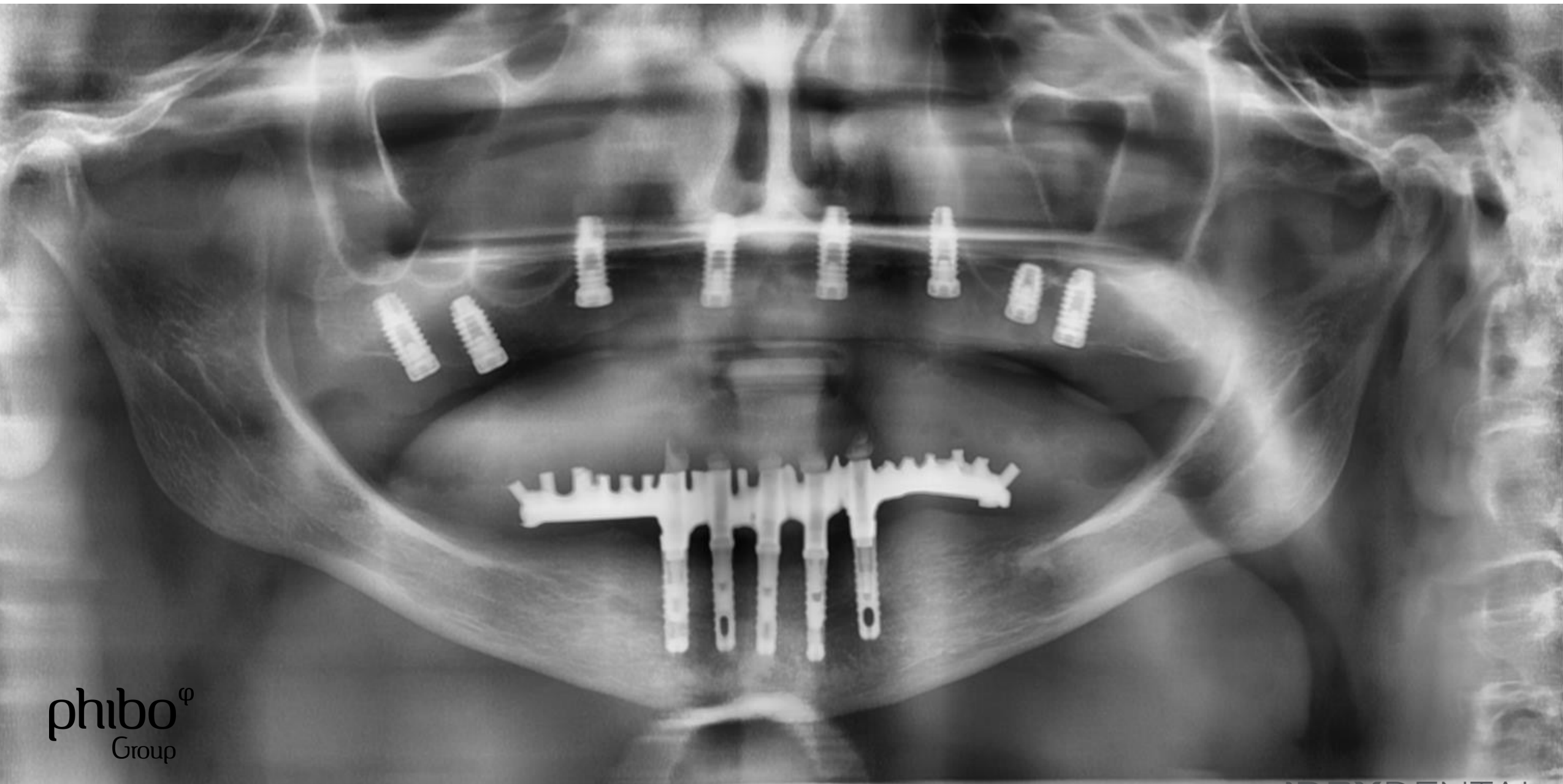








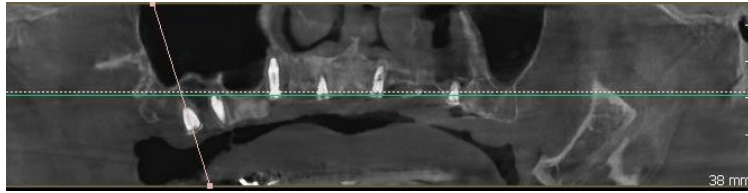




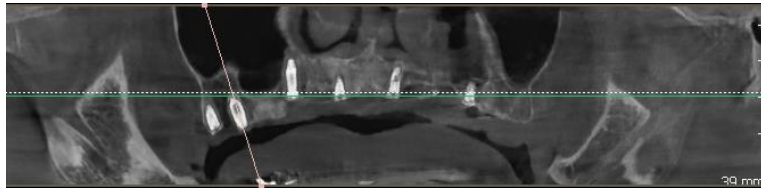
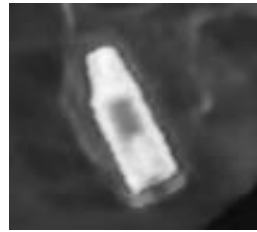
phibo^φ
Group

Dr. Jesús García de Blas y Dra. María Sánchez


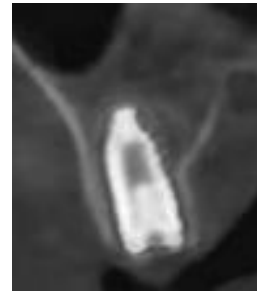
IDEXDENTAL
INSTITUTO DENTAL EXTREMEÑO



IOI 17: s4x10 a 5N

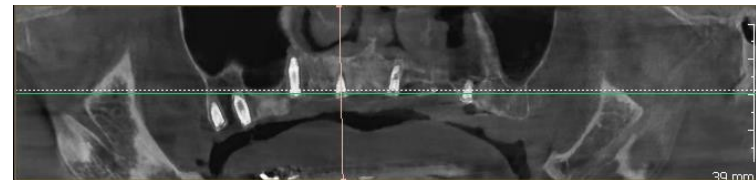
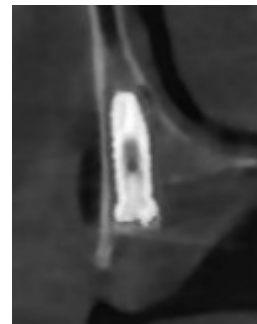


IOI 16: s4x8,5 a 10N



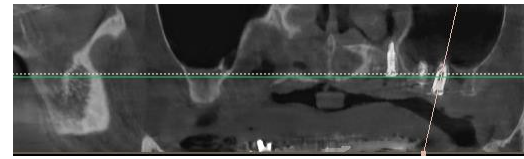
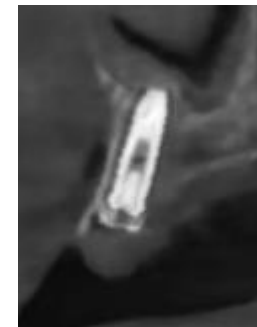IOI 14: s3x10 a 35N

- loi ligeramente angulado y palatizado

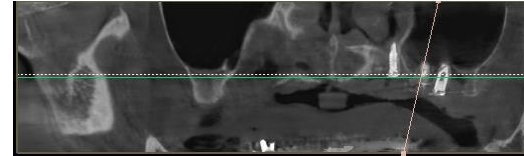
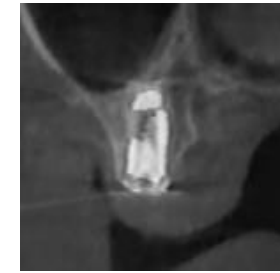

IOI 12: s3x10 a 35N

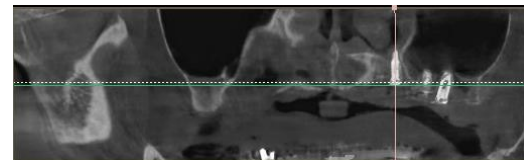
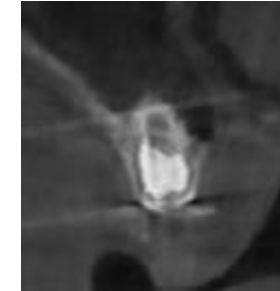
- loi palatinizado
- Anclado en fosa nasal



IOI 26: s4x10 a 5N

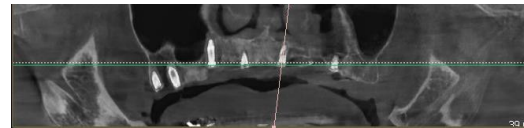


IOI 25: s4x6 a 10N



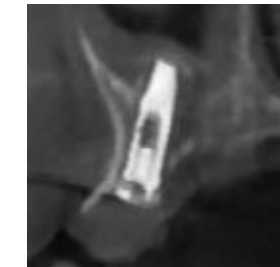IOI 24: s3x10 a 35N

- loi ligeramente angulado y palatizado



IOI 22: s3x10 a 35N

- loi palatinizado
- Anclado en fosa nasal



phibo^φ
Group