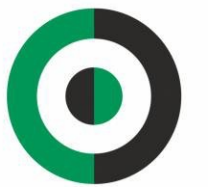



*Dr. Jesús García de Blas y
Dra. María Sánchez*



empresa
extremeña

IDEXDENTAL
— INSTITUTO DENTAL EXTREMEÑO —

- *Paciente Femenina
- *Enfermedad Periodontal crónica
- *Pérdida de múltiples piezas

Plan de tratamiento:

Exodoncia de todos los órganos dentarios y
Rehabilitación s/implantes TSH con carga
inmediata en ambas arcadas.



phibo[®]

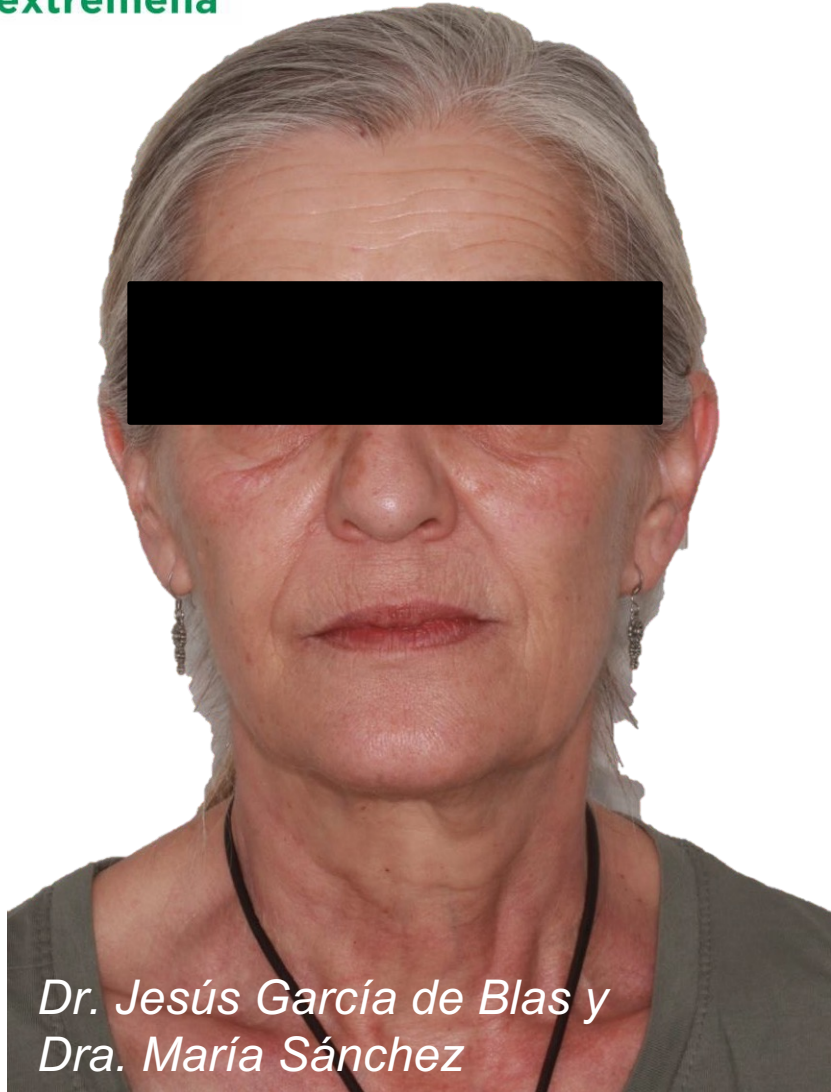*Dr. Jesús García de Blas y
Dra. María Sánchez*



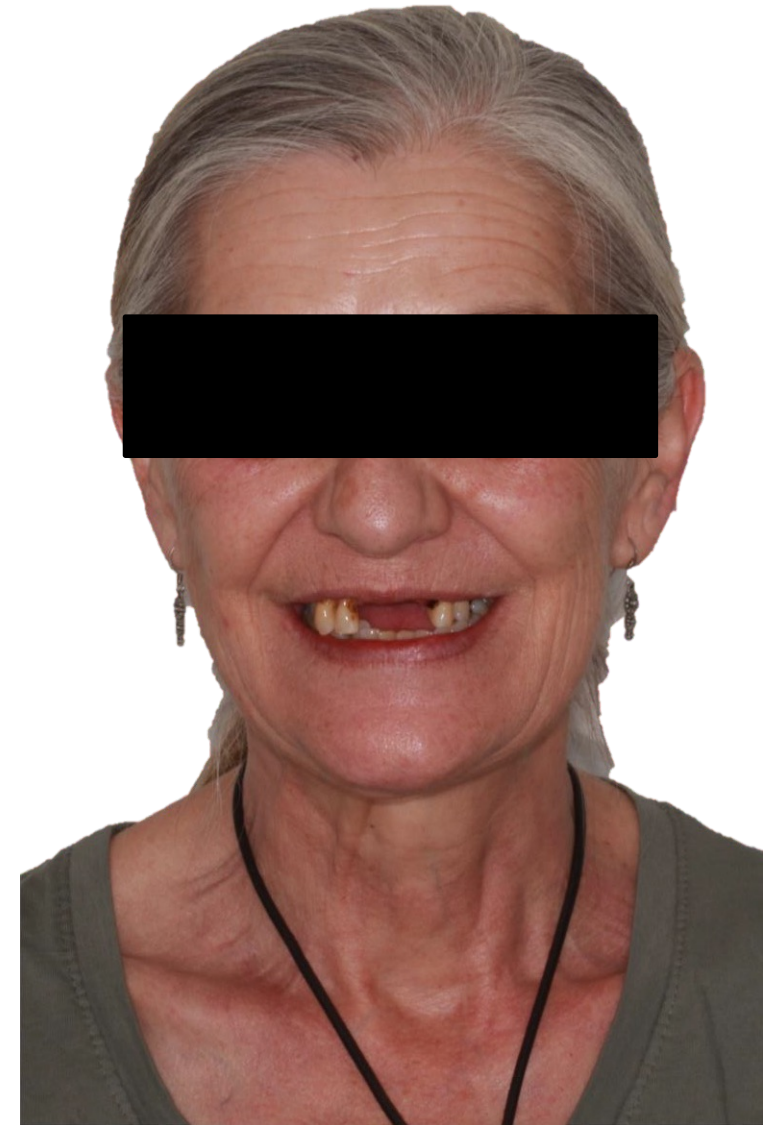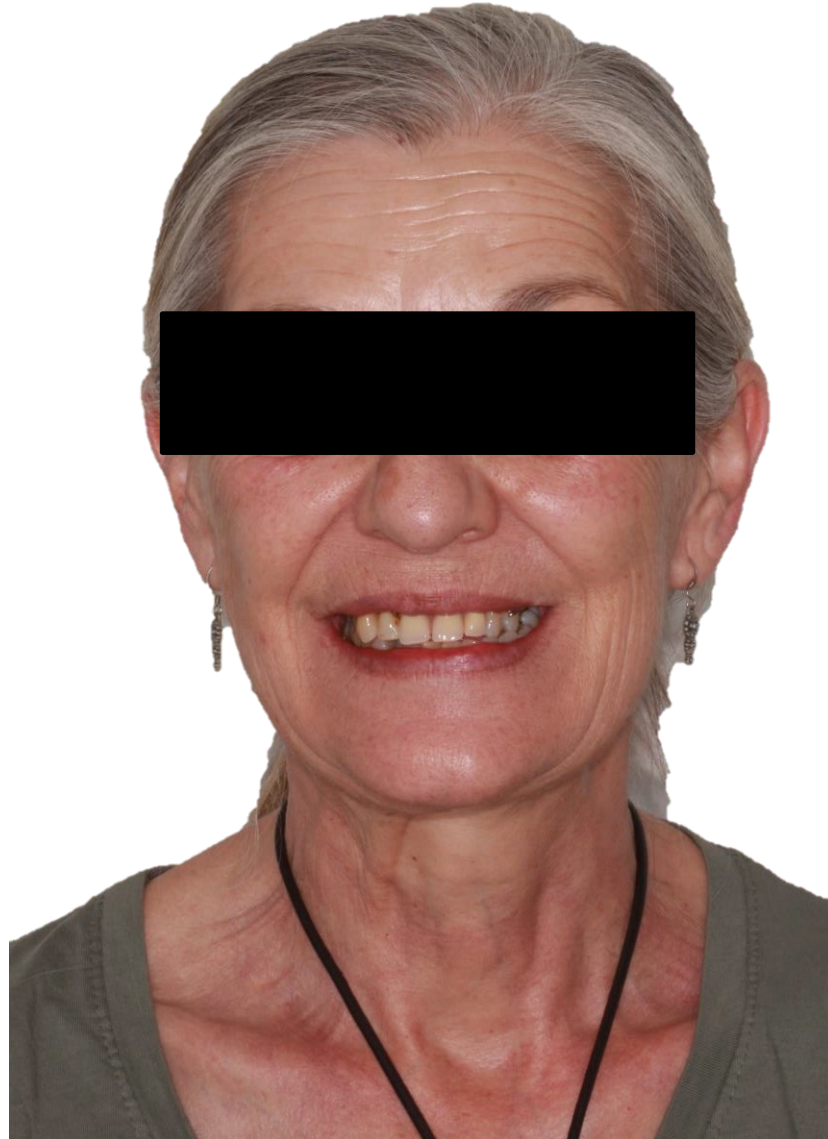empresa
extremeña

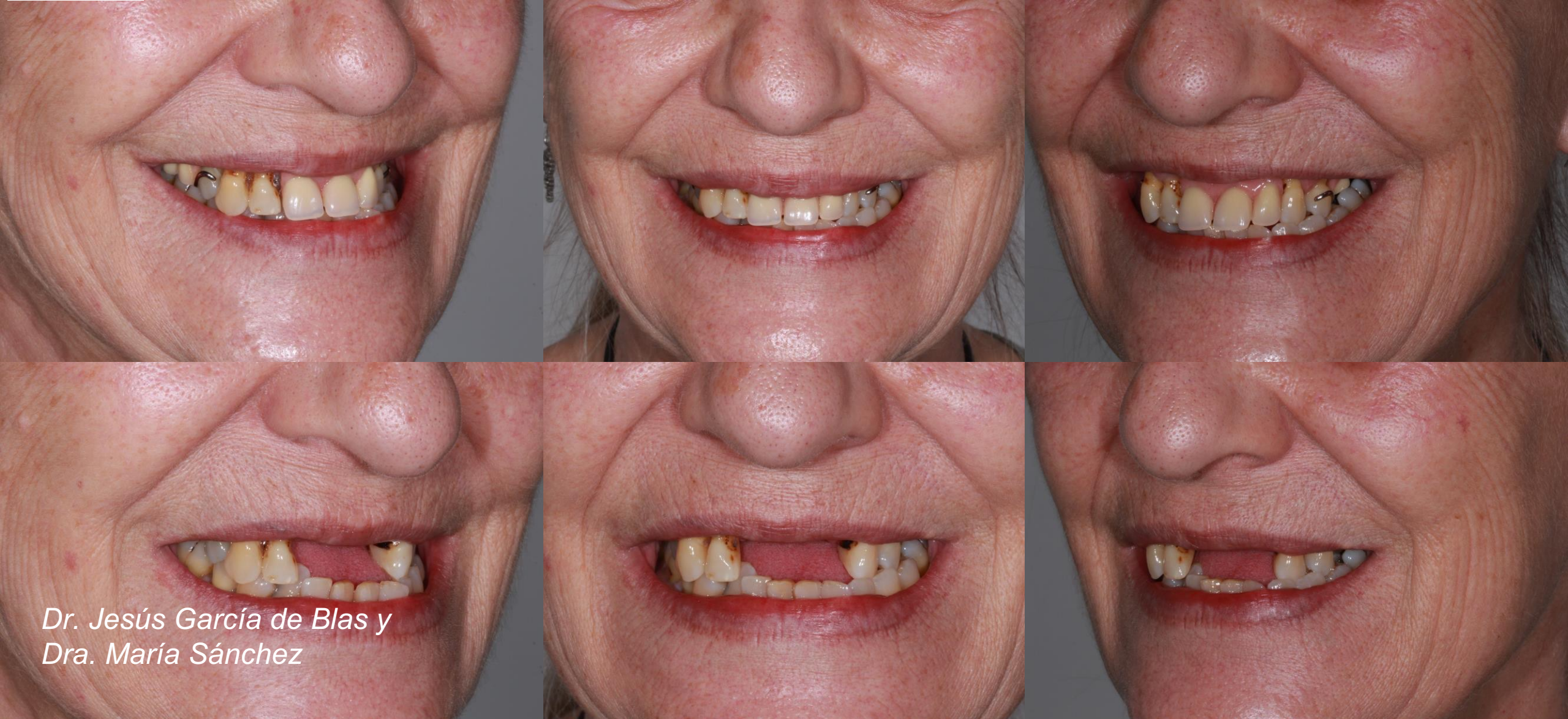IDEXDENTAL
— INSTITUTO DENTAL EXTREMEÑO —

phibo^φ

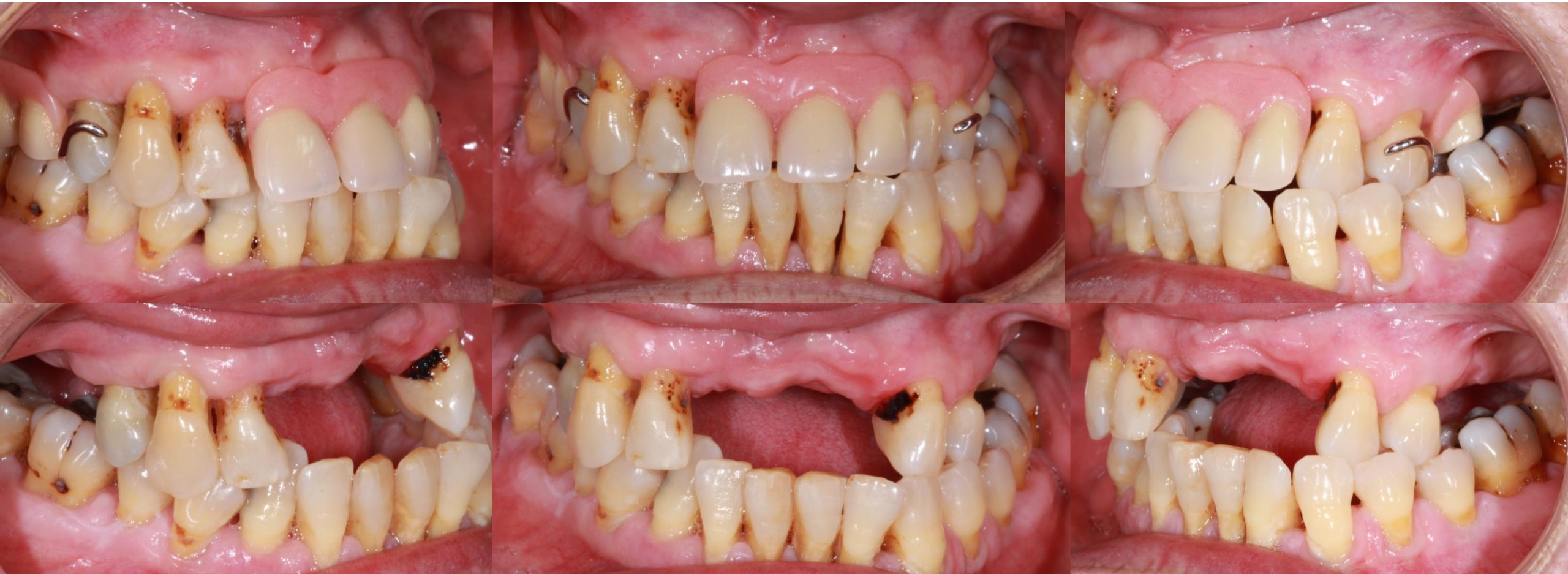

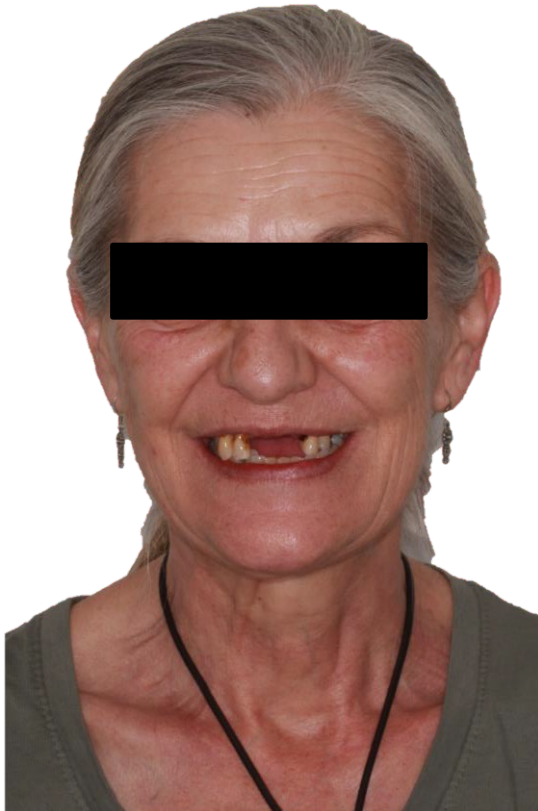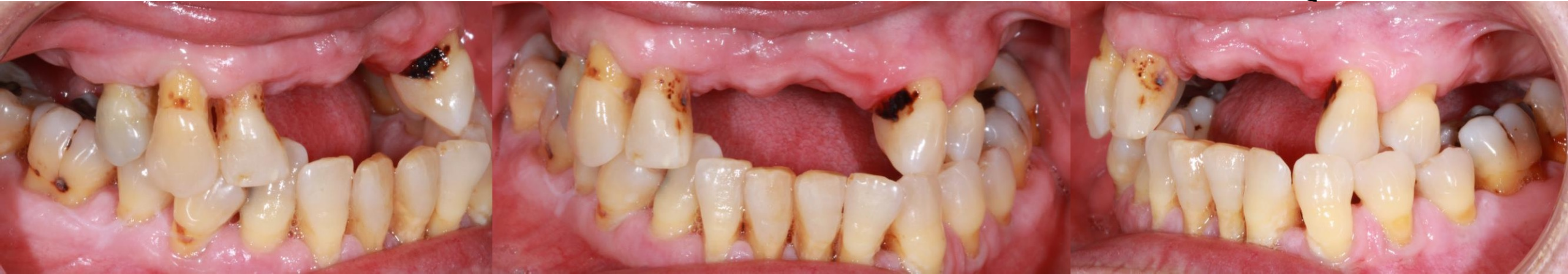*Dr. Jesús García de Blas y
Dra. María Sánchez*





*Dr. Jesús García de Blas y
Dra. María Sánchez*





SITUACIÓN INICIAL DE LA PACIENTE:

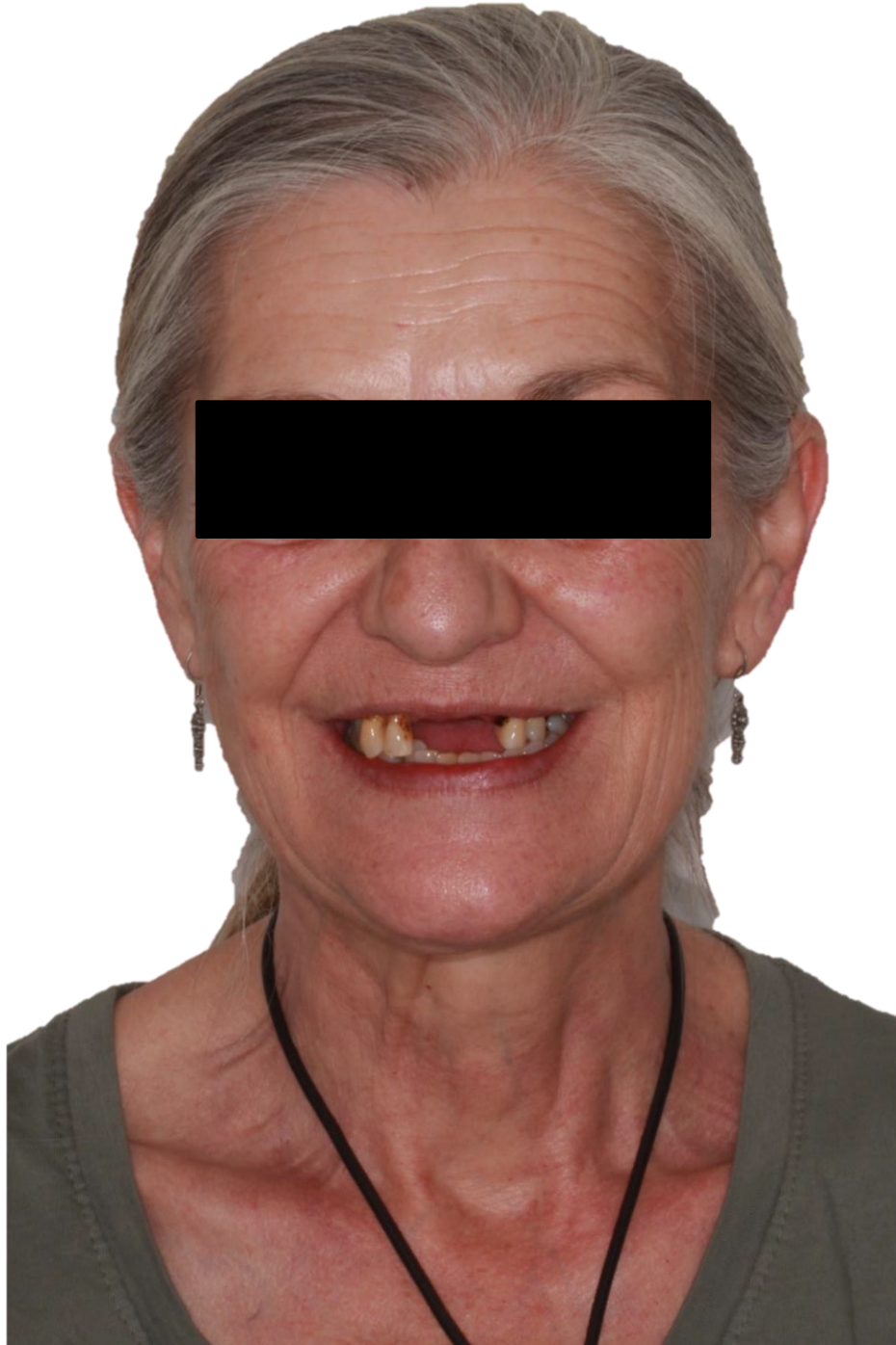- Arcada superior
 - Pérdida del 85% de las piezas
 - Presencia de pérdida ósea alrededor de las piezas remanentes
 - Caries en piezas 12 y 23
- Arcada inferior:
 - Movilidad en el 80% de las piezas
 - Extrusión del sector posterior
 - Mordida cruzada en lado izquierdo

phibo[®]

IDEXDENTAL
— INSTITUTO DENTAL EXTREMEÑO —

PLAN DE TRATAMIENTO:

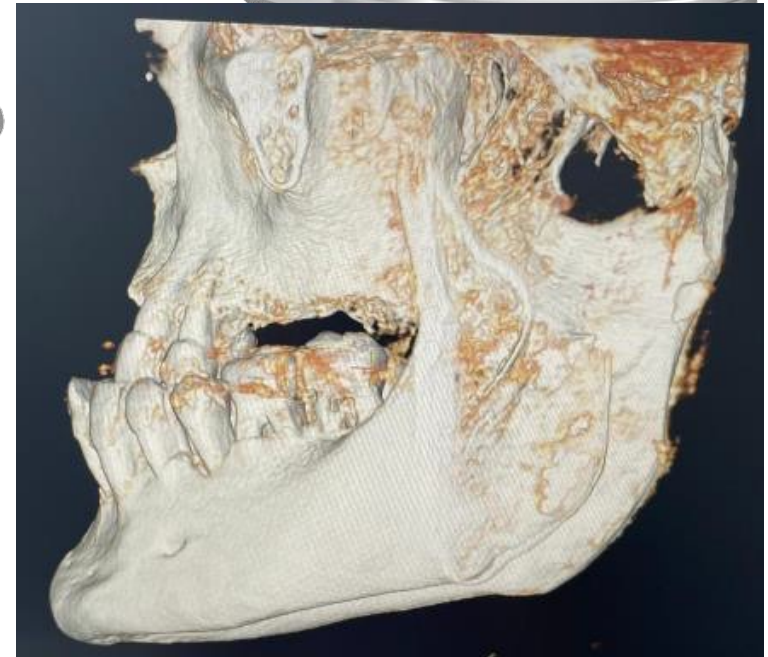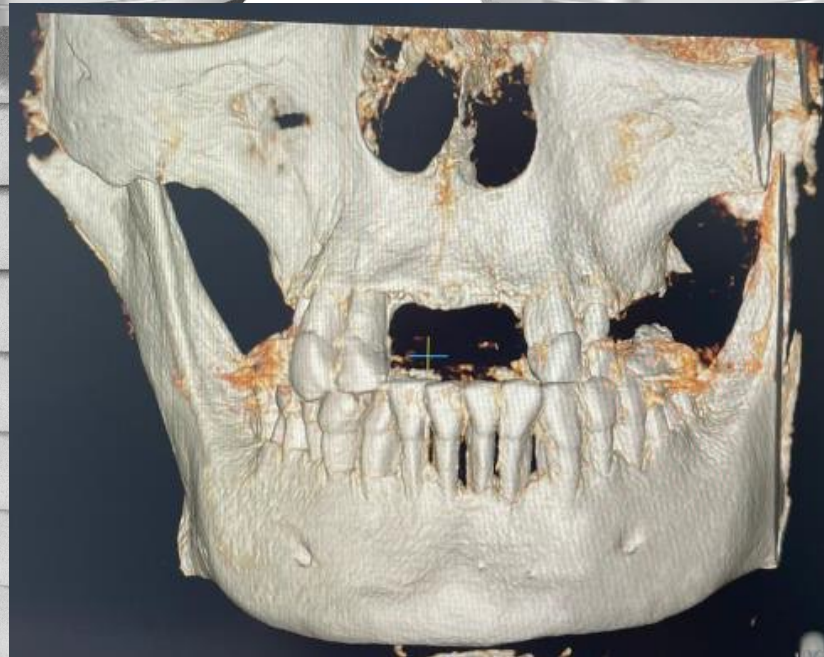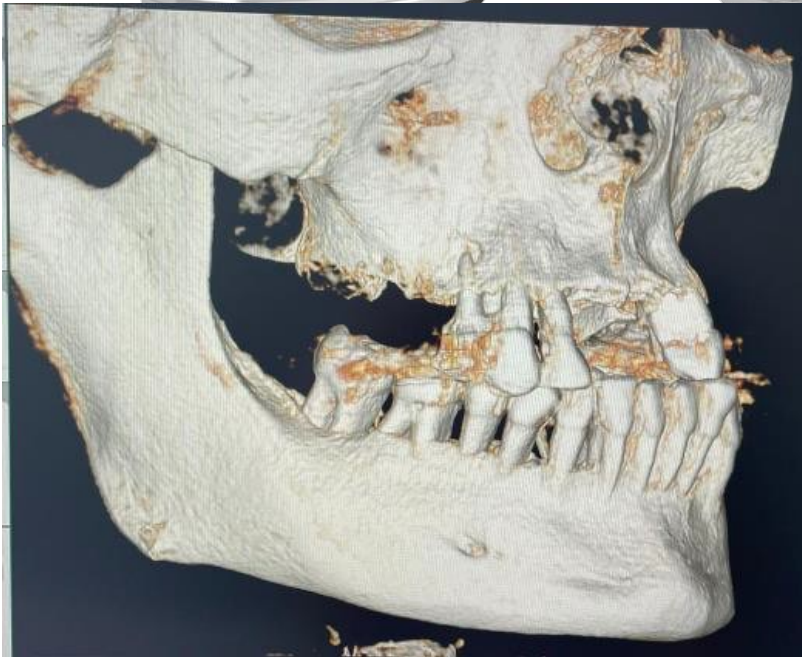- Extracción de piezas superiores e inferior y colocación de 6 IOIs TSH Phibo superior e inferior
- Colocación de cargas inmediatas superior e inferior en el mismo momento de la cirugía
 - Previo estudio DSD
- 48 horas después, colocación de carga inmediata de laboratorio



IDEXDENTAL

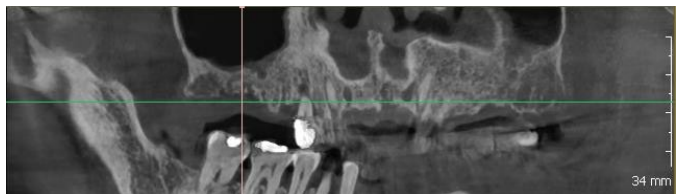
INSTITUTO DENTAL EXTREMEÑO

phibo[®]

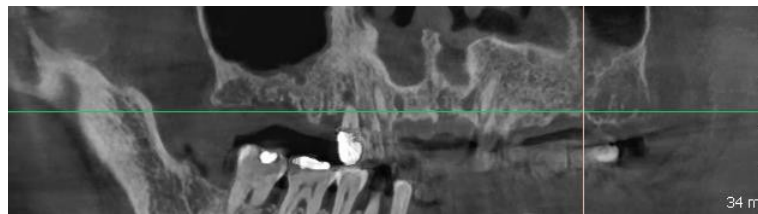
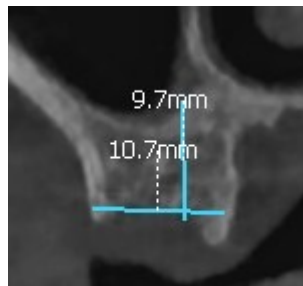


*Dr. Jesús García de Blas y
Dra. María Sánchez*

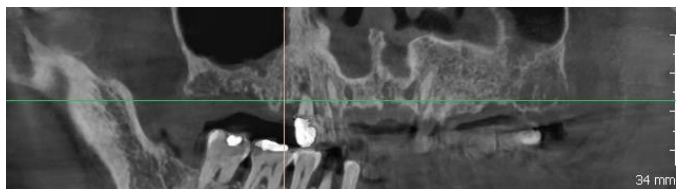
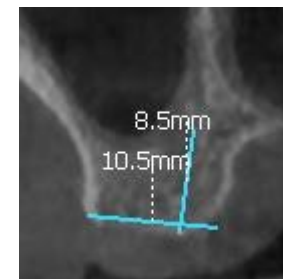
phibo^φ



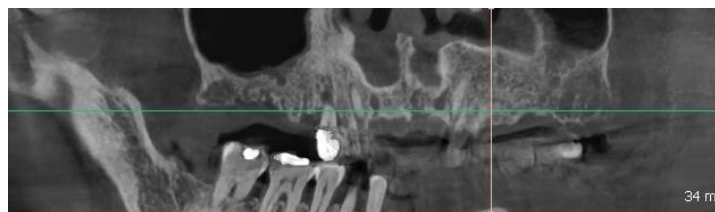
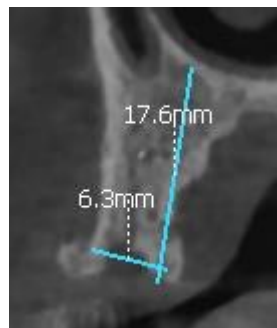
IOI 16: S4X10



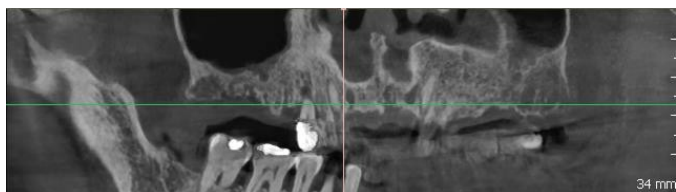
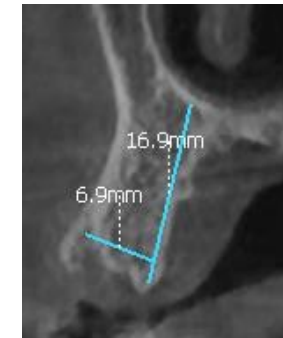
IOI 26: S4X10



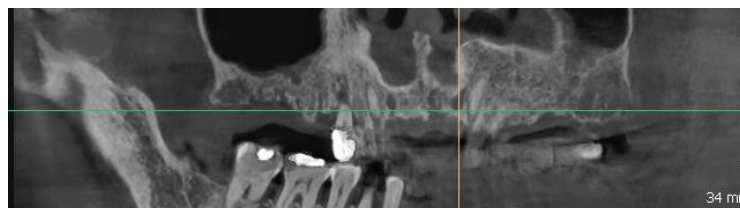
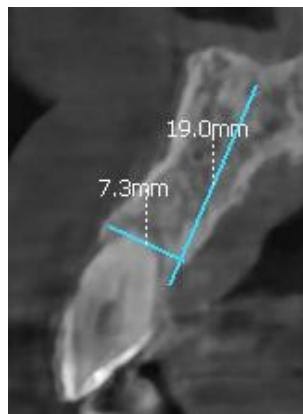
IOI 14: S3X13



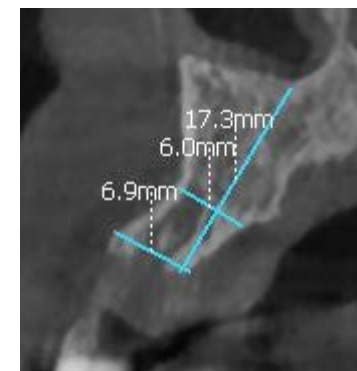
IOI 24: S3X13



IOI 12: S3X13



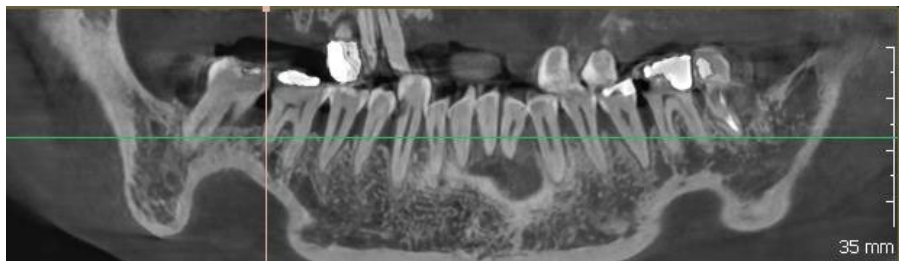
IOI 13X13



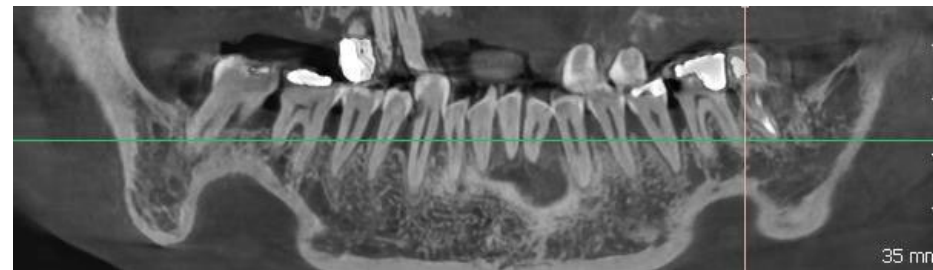
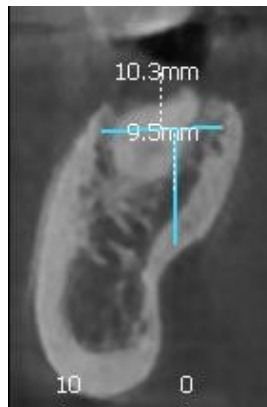
*Dr. Jesús García de Blas y
Dra. María Sánchez*

IDEXDENTAL
INSTITUTO DENTAL EXTREMEÑO

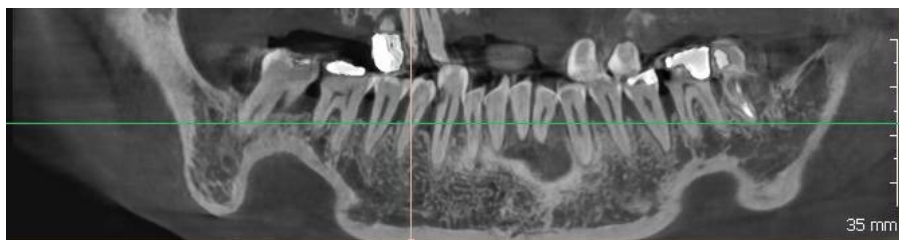
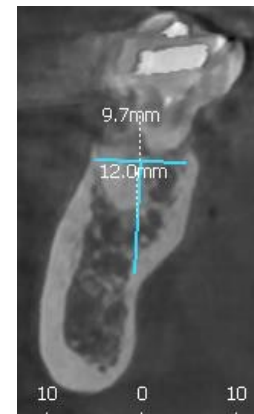




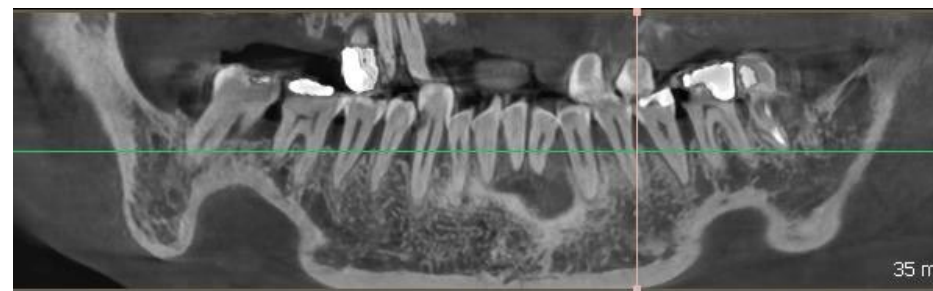
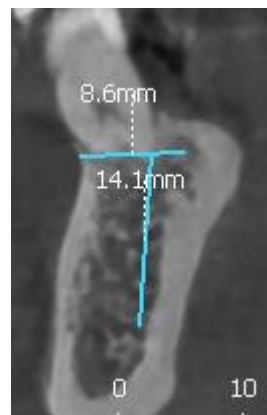
IOI 46:S4X8,5



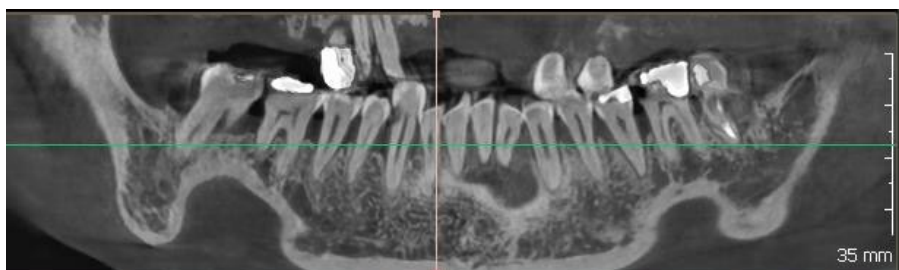
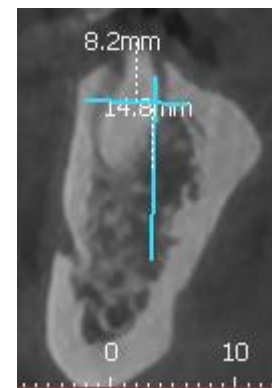
IOI 36:S4X8,5



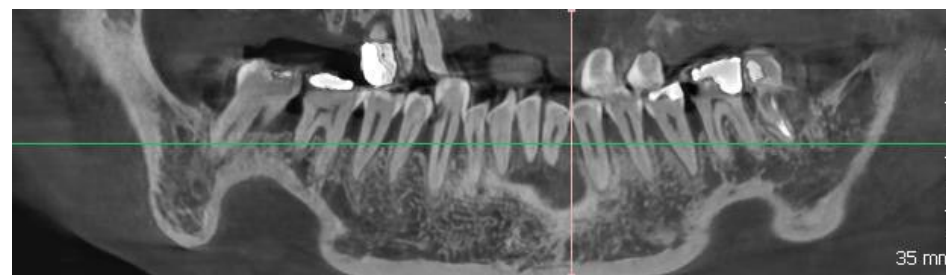
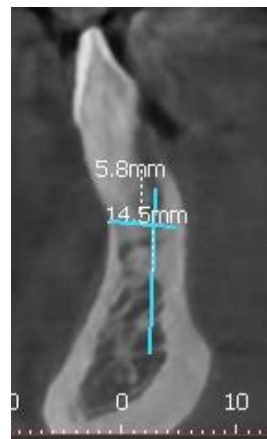
IOI 44: S3X11,5



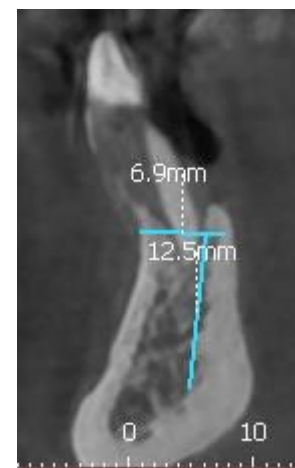
IOI 16: S3X11,5



IOI 42: S3X10



IOI 32: S3X10





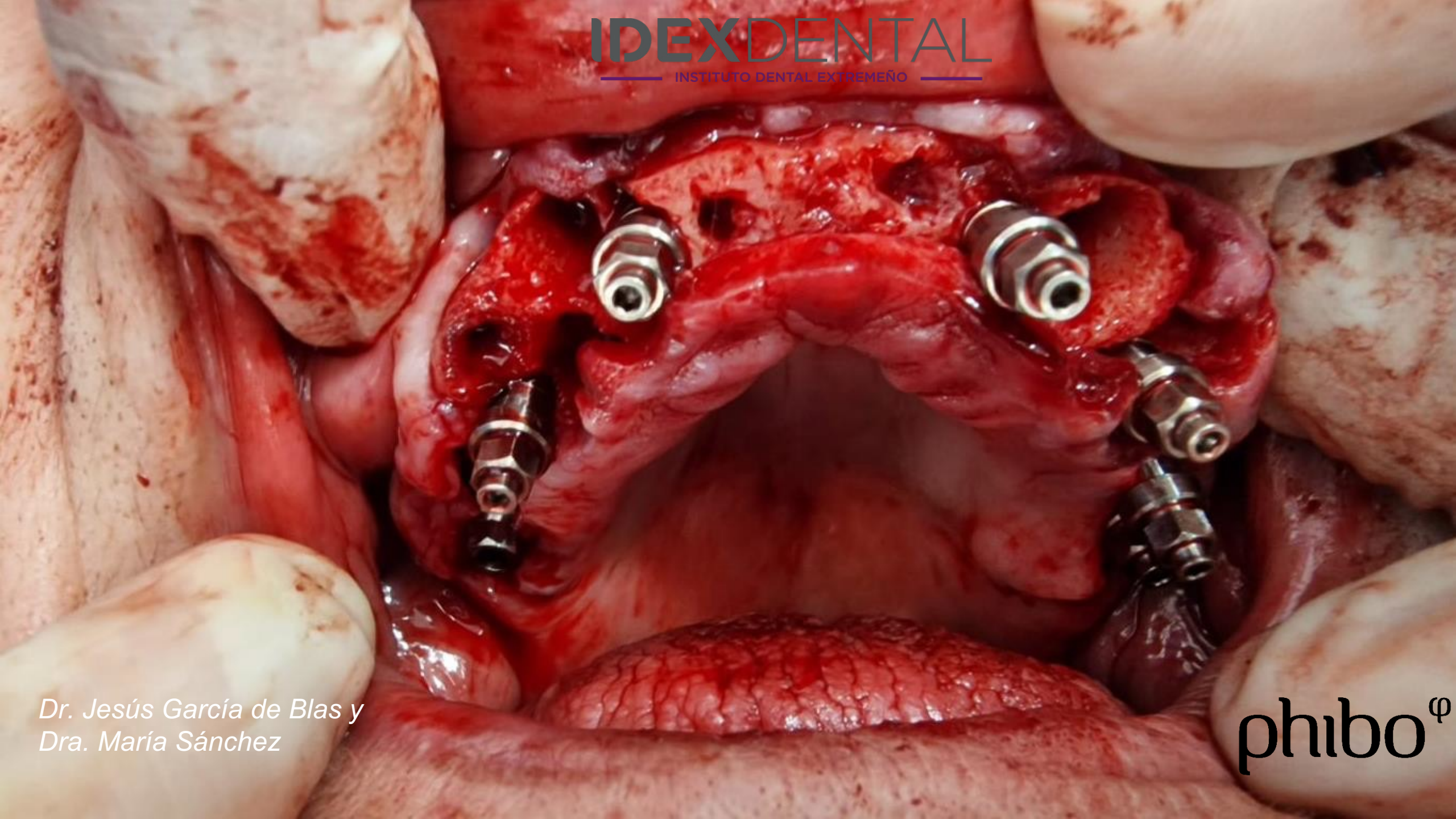
IDEXDENTAL
— INSTITUTO DENTAL EXTREMEÑO —

*Dr. Jesús García de Blas y
Dra. María Sánchez*

phibo[®]

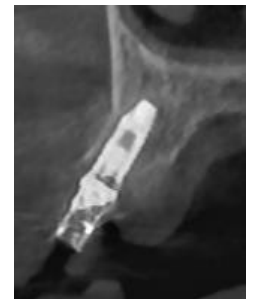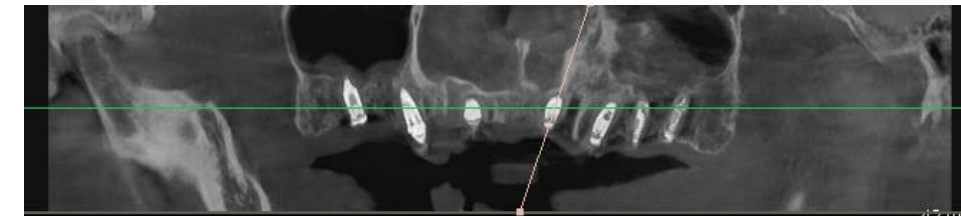
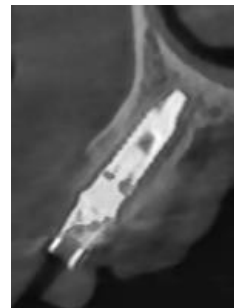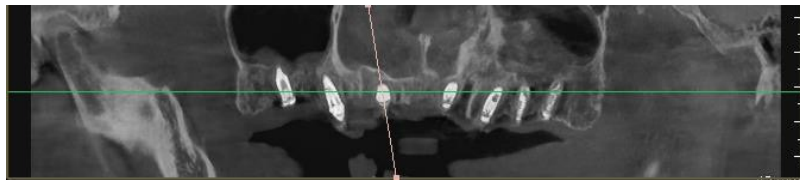
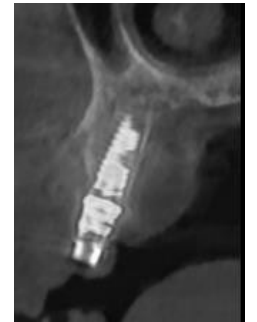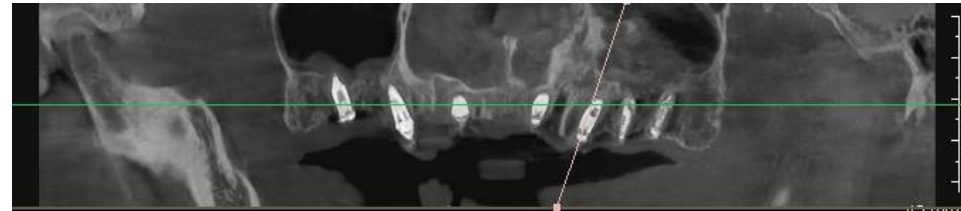
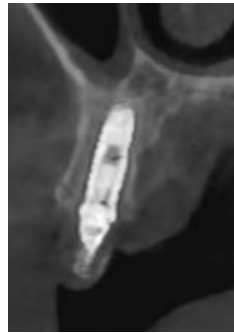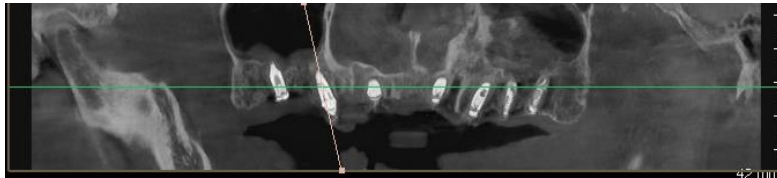
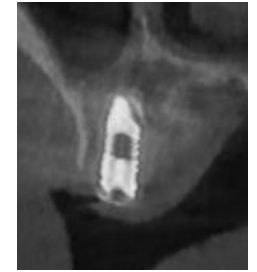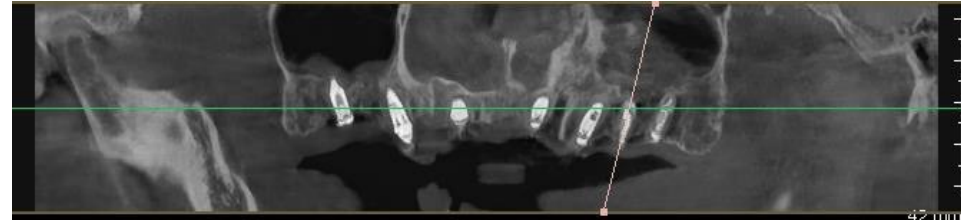
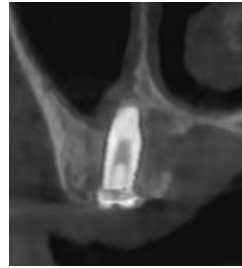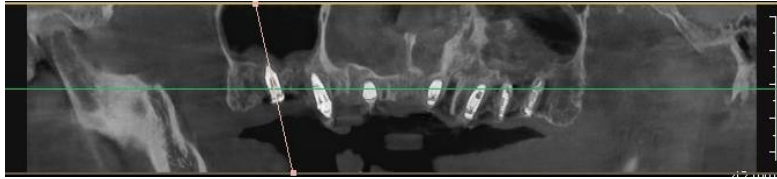
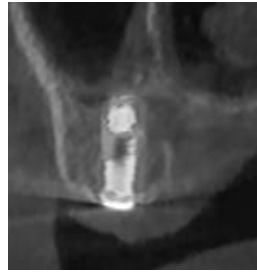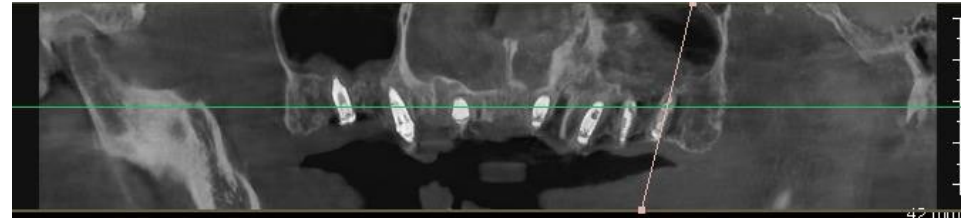
*Dr. Jesús García de Blas y
Dra. María Sánchez*

phibo[®]



*Dr. Jesús García de Blas y
Dra. María Sánchez*

phibo[®]

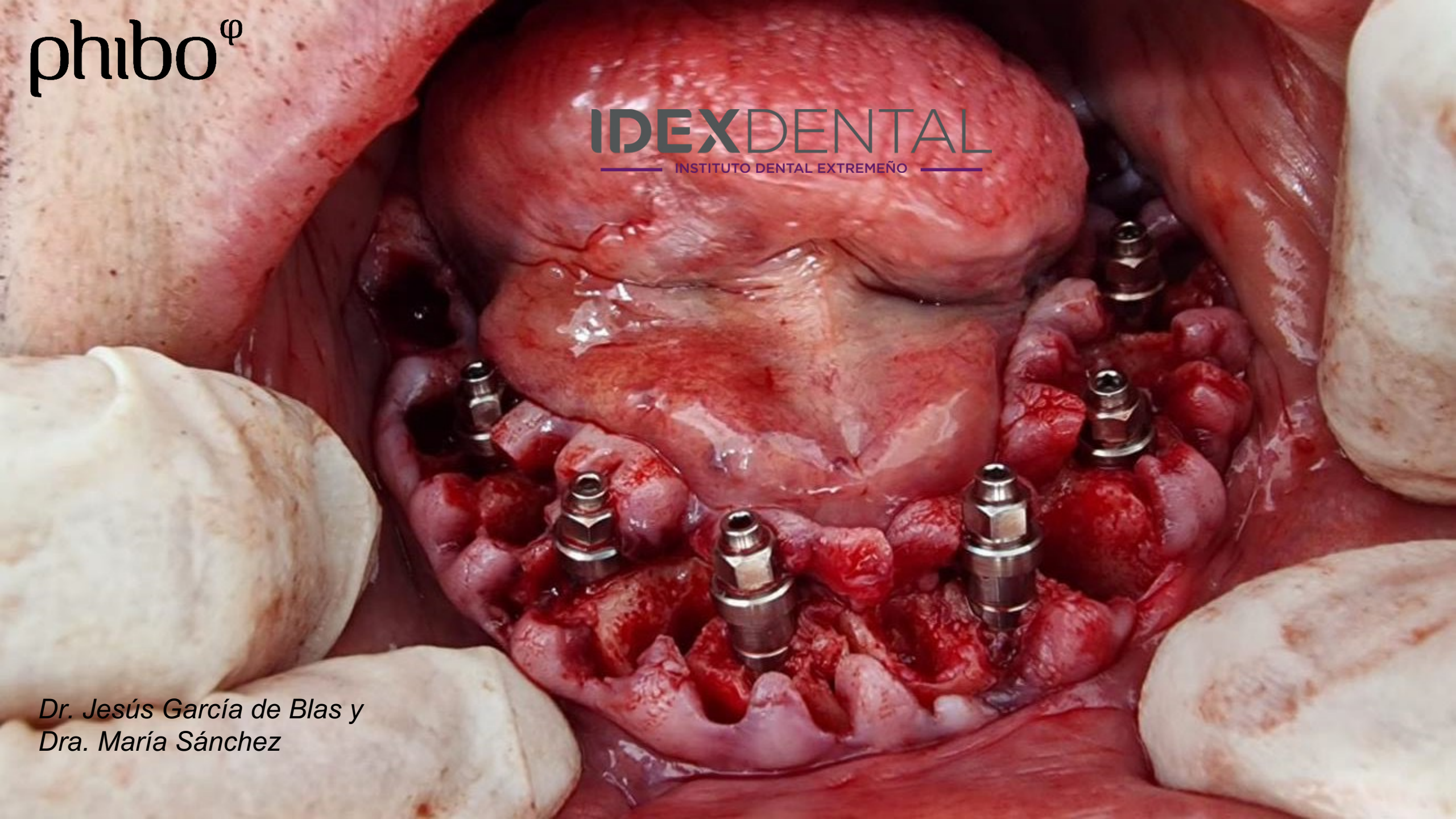


*Dr. Jesús García de Blas y
Dra. María Sánchez*

phibo[®]

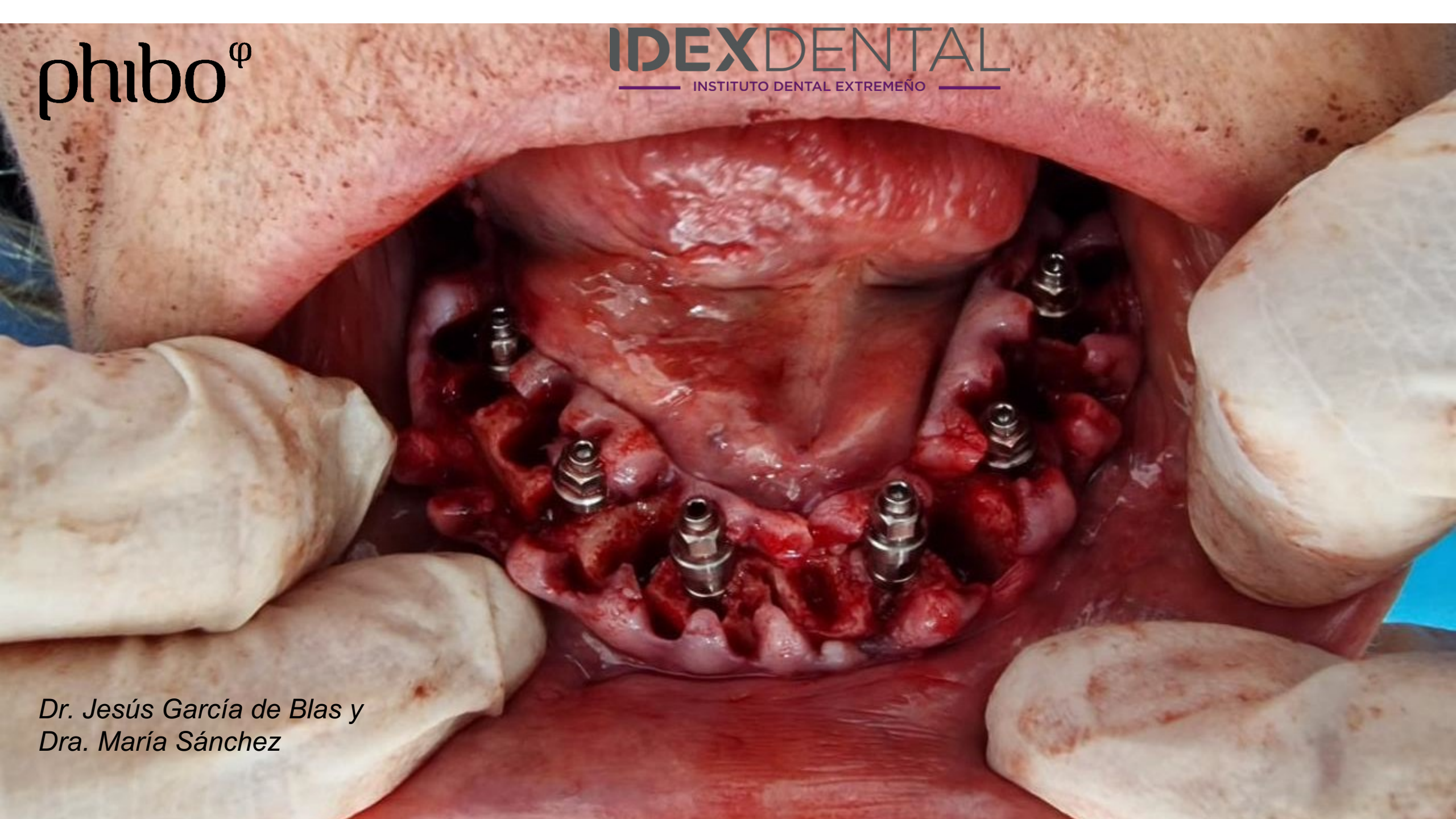IDEXDENTAL
— INSTITUTO DENTAL EXTREMEÑO —

*Dr. Jesús García de Blas y
Dra. María Sánchez*

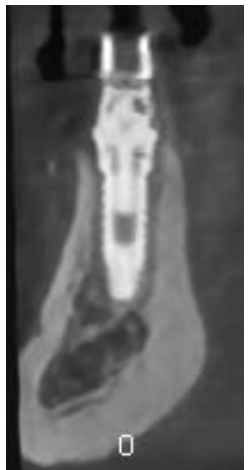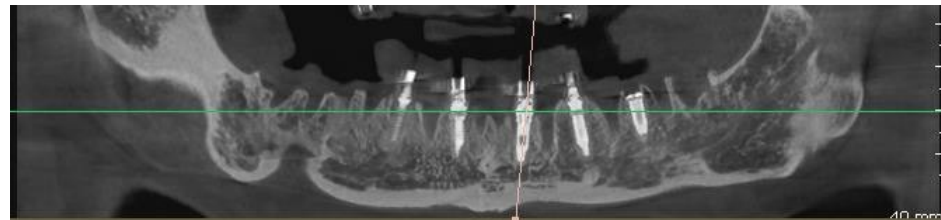
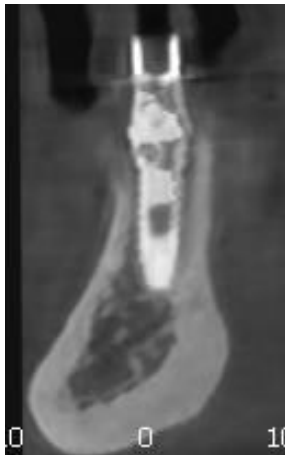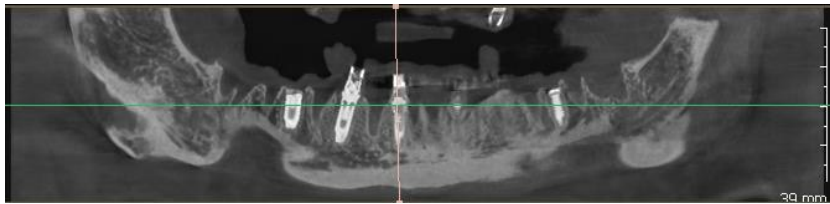
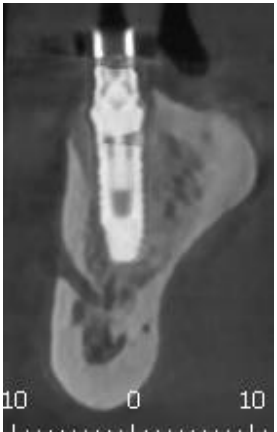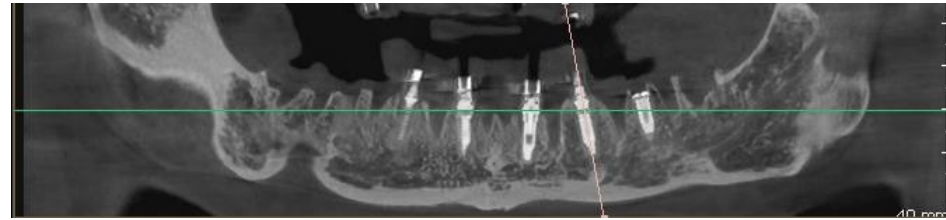
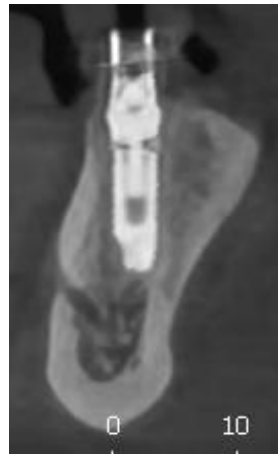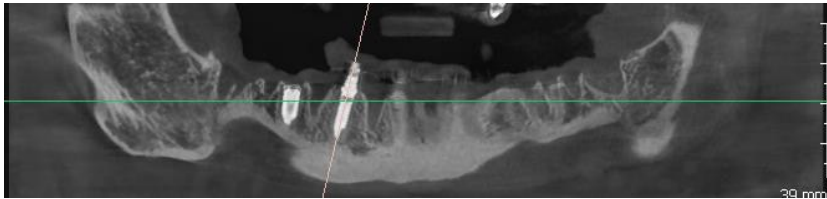
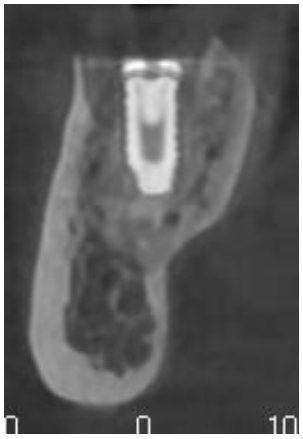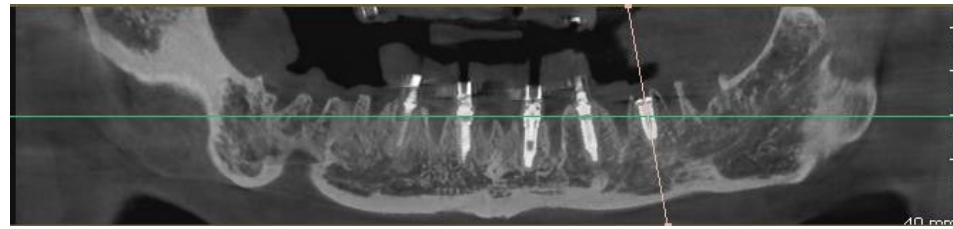
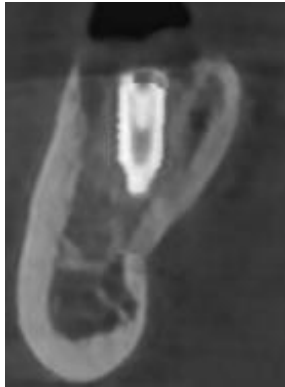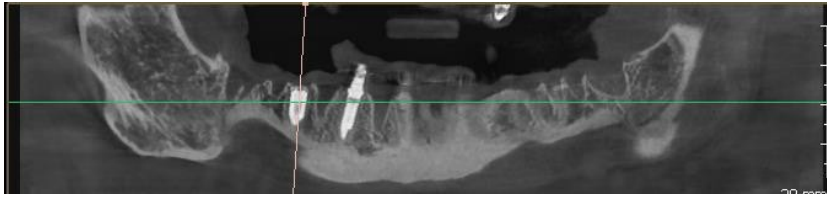


phibo^φ

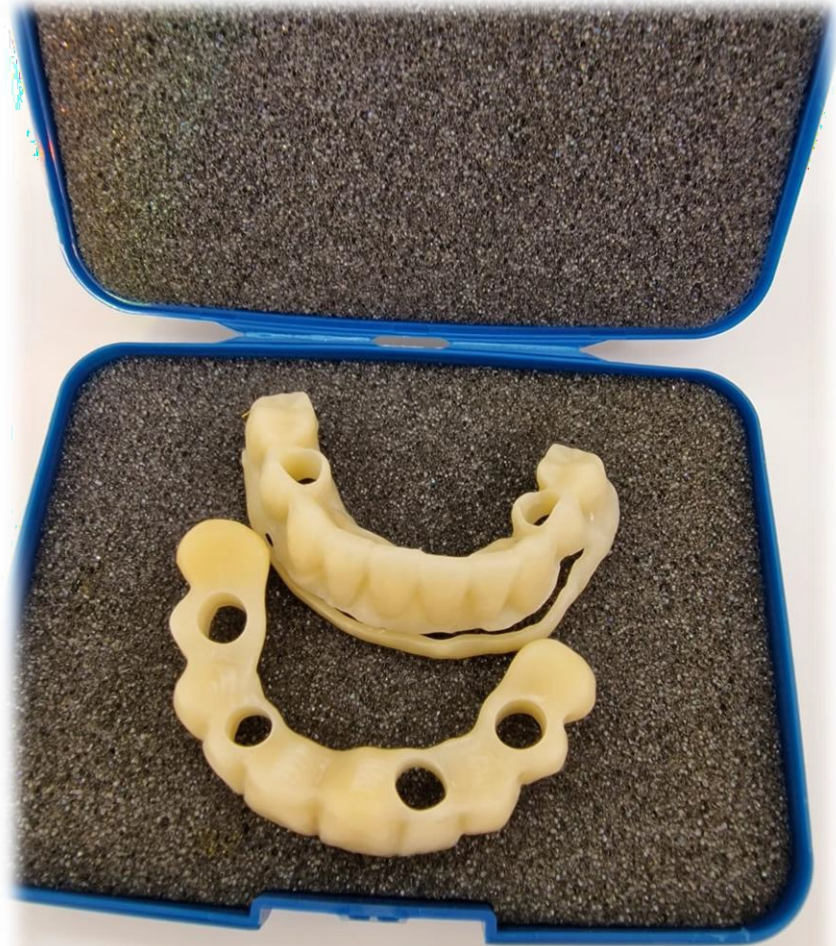IDEXDENTAL
— INSTITUTO DENTAL EXTREMEÑO —



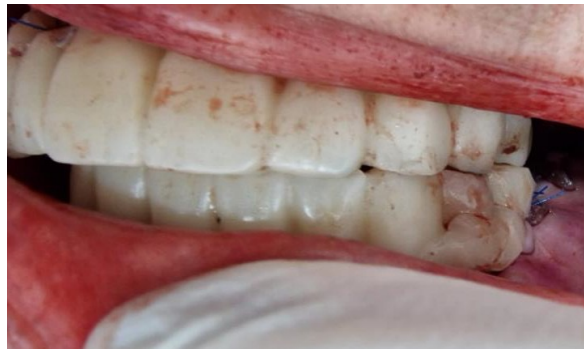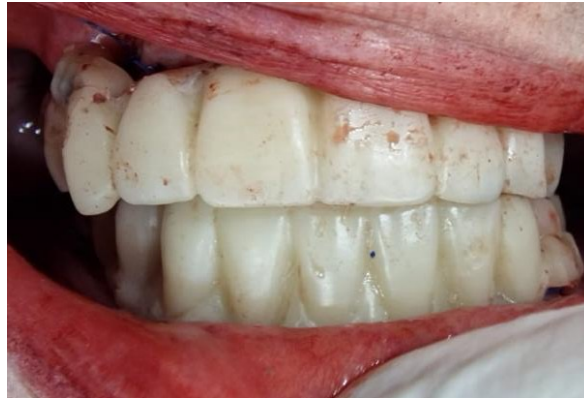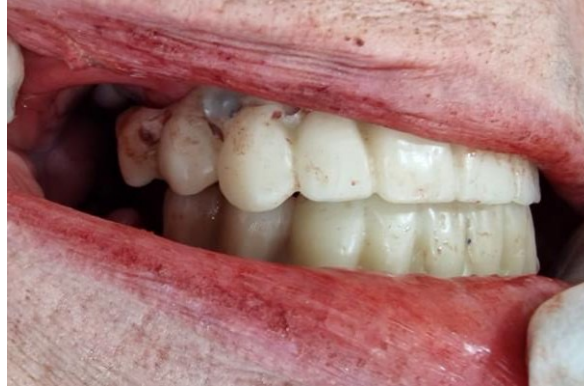*Dr. Jesús García de Blas y
Dra. María Sánchez*



*Dr. Jesús García de Blas y
Dra. María Sánchez*




Dr. Jesús García de Blas y
Dra. María Sánchez

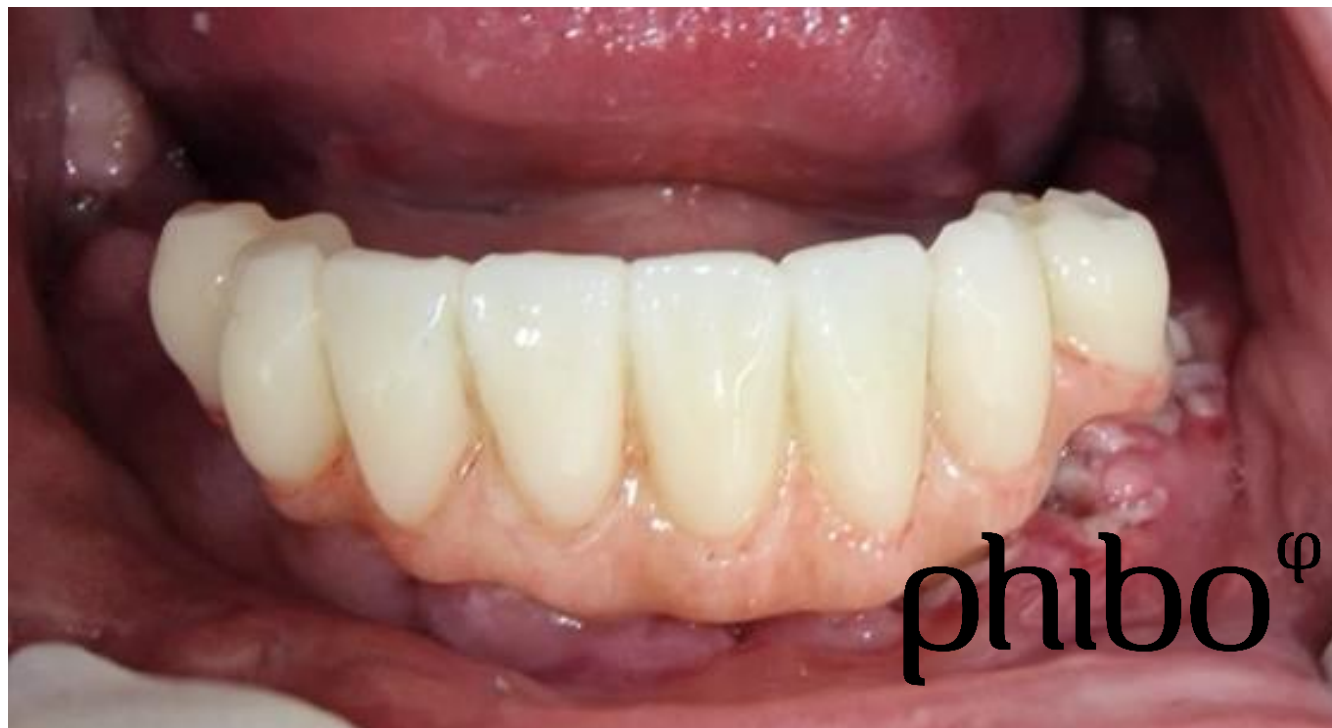
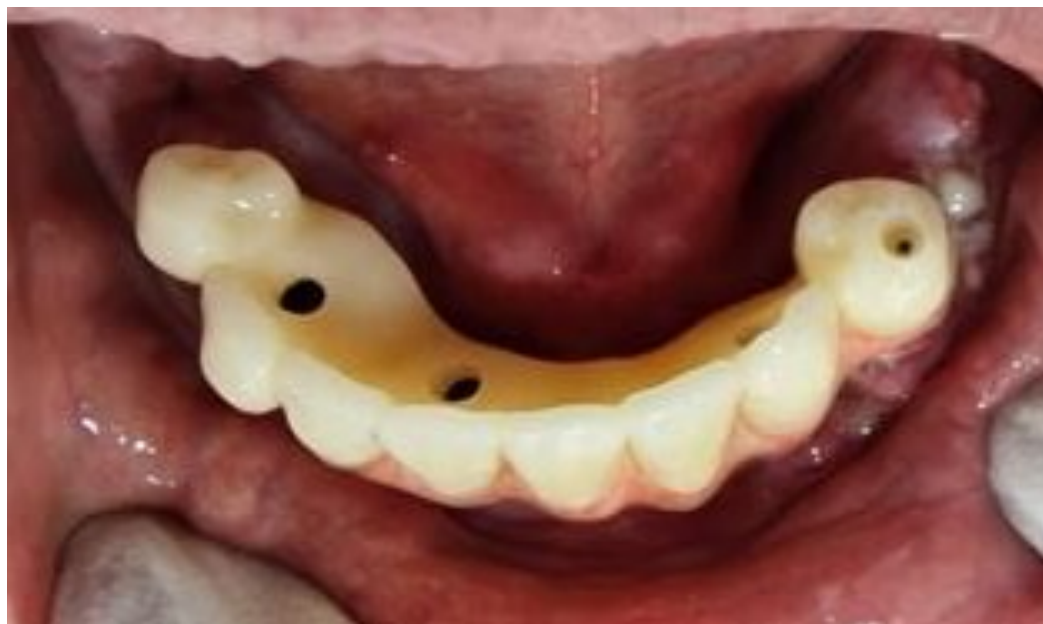
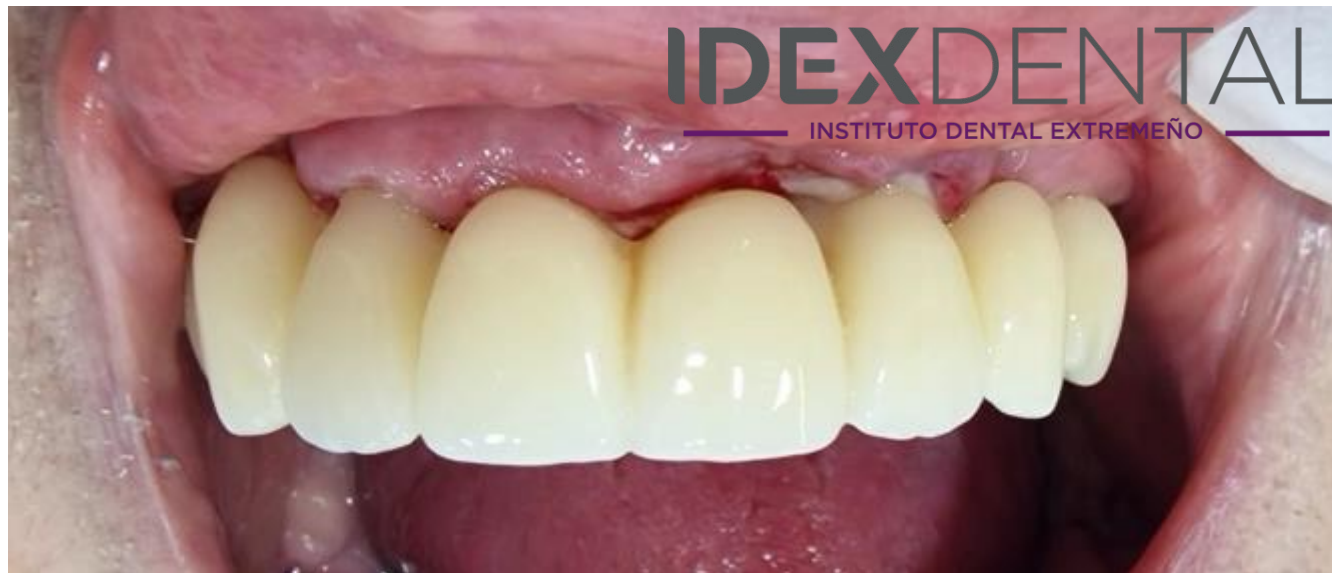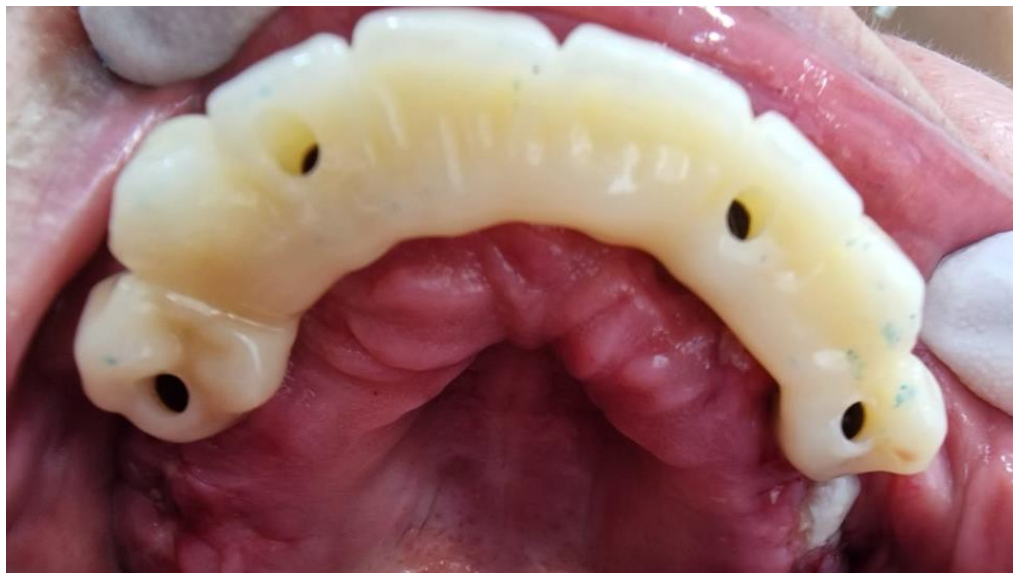phibo[®]

Gallucci fresada.

- Ajusto oclusión
- Escaneo con pre-preparación
- Pido carga inmediata de laboratorio
- Mantengo gallucci dos días en boca



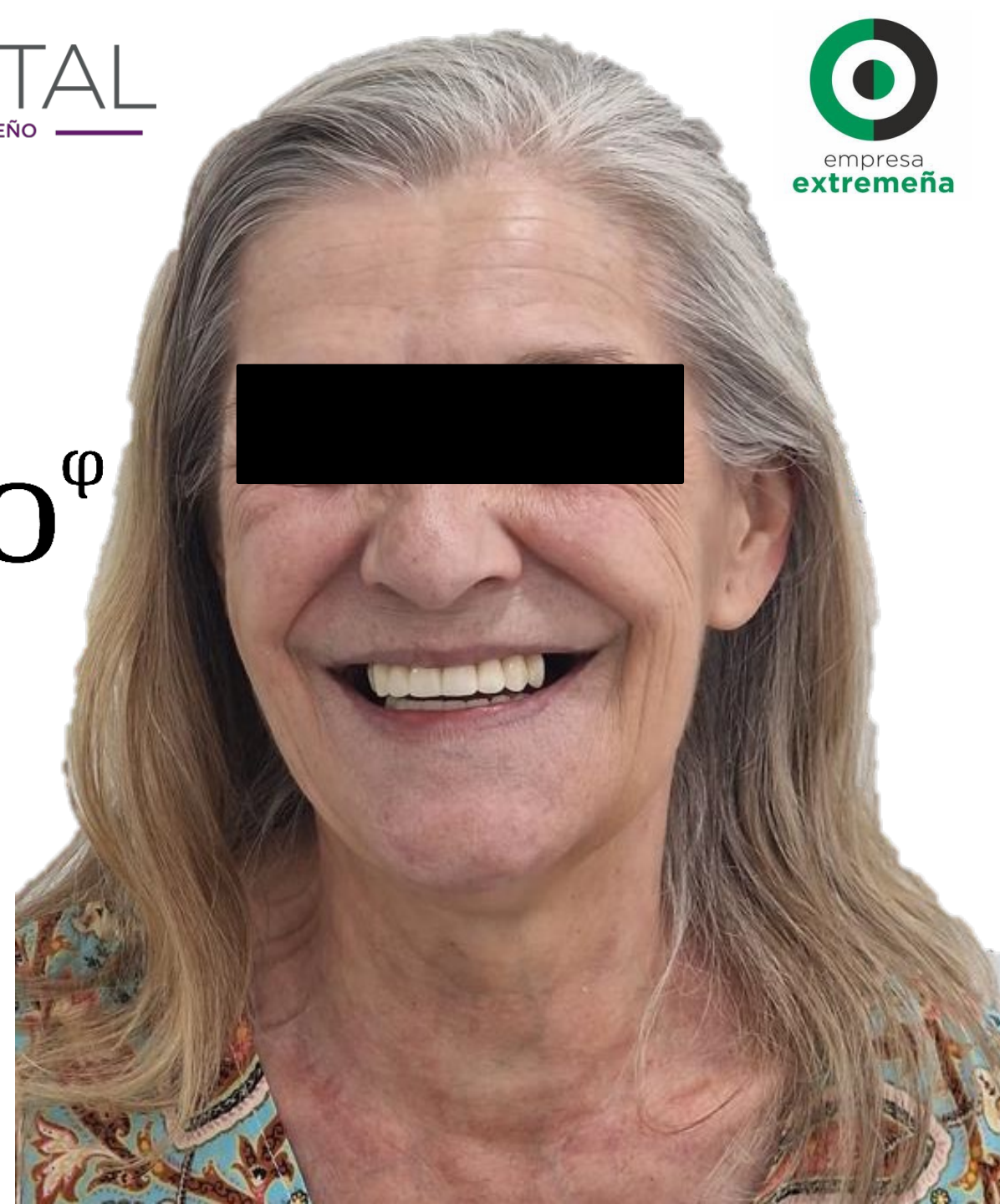


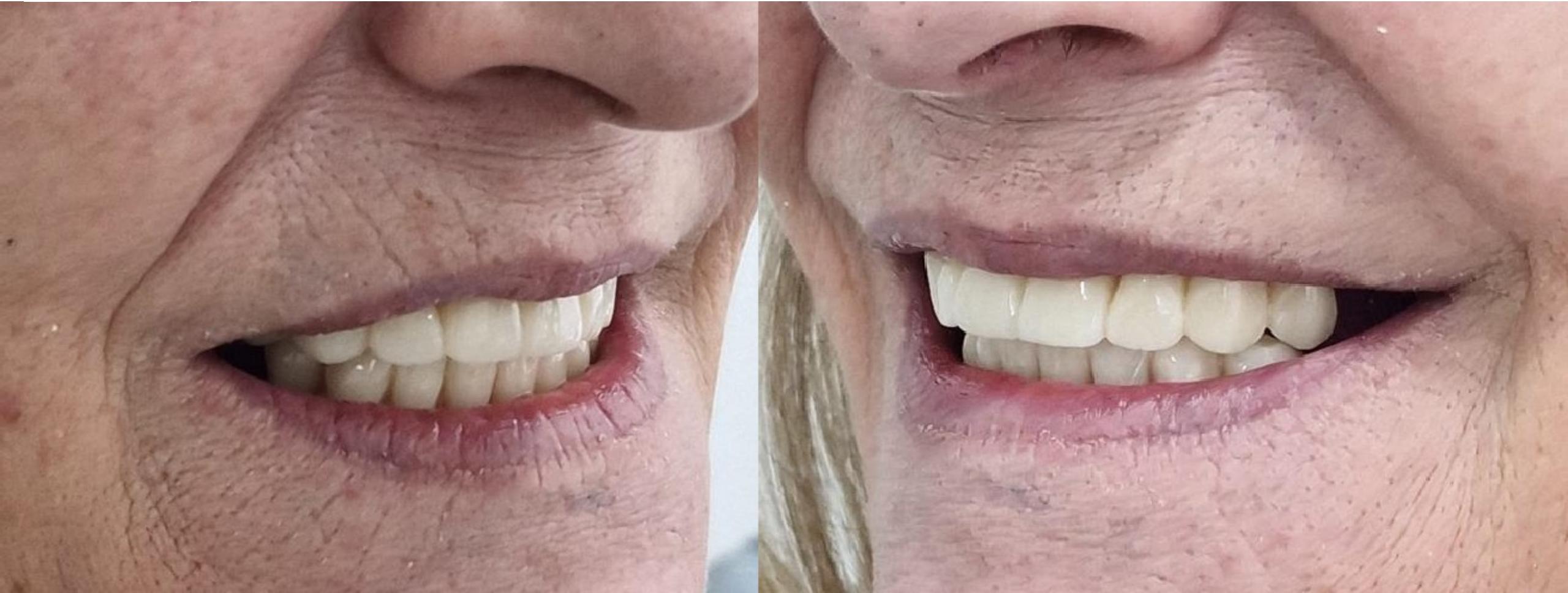*Dr. Jesús García de Blas y
Dra. María Sánchez*



*Dr. Jesús García de Blas y
Dra. María Sánchez*

phibo^φ





*Dr. Jesús García de Blas y
Dra. María Sánchez*

phibo[®]

*Dr. Jesús García de Blas y
Dra. María Sánchez*

IDEXDENTAL
INSTITUTO DENTAL EXTREMEÑO