



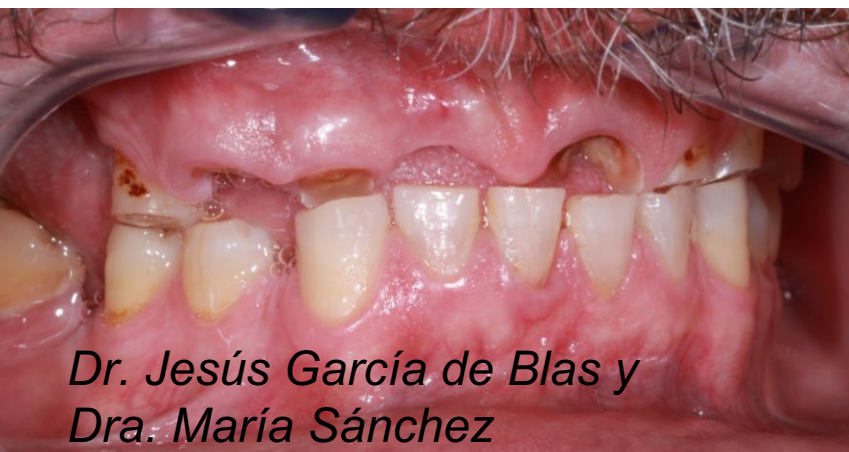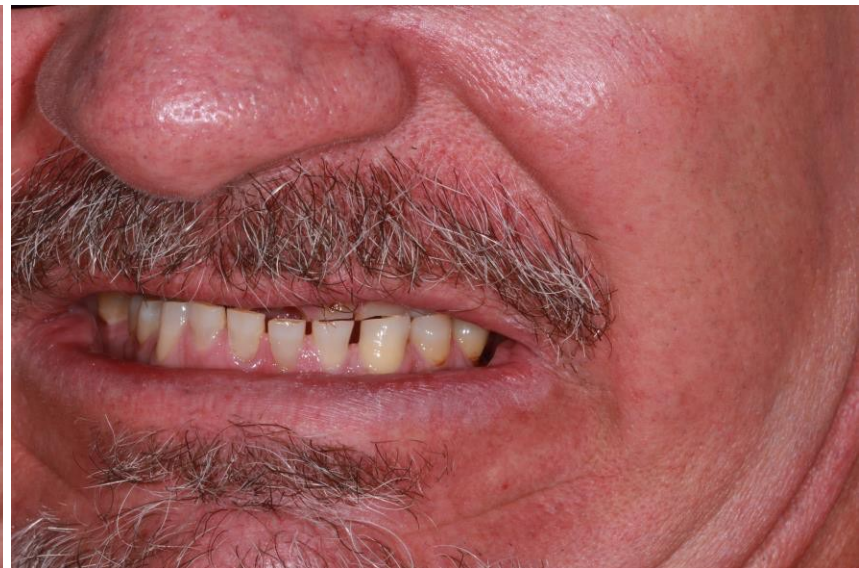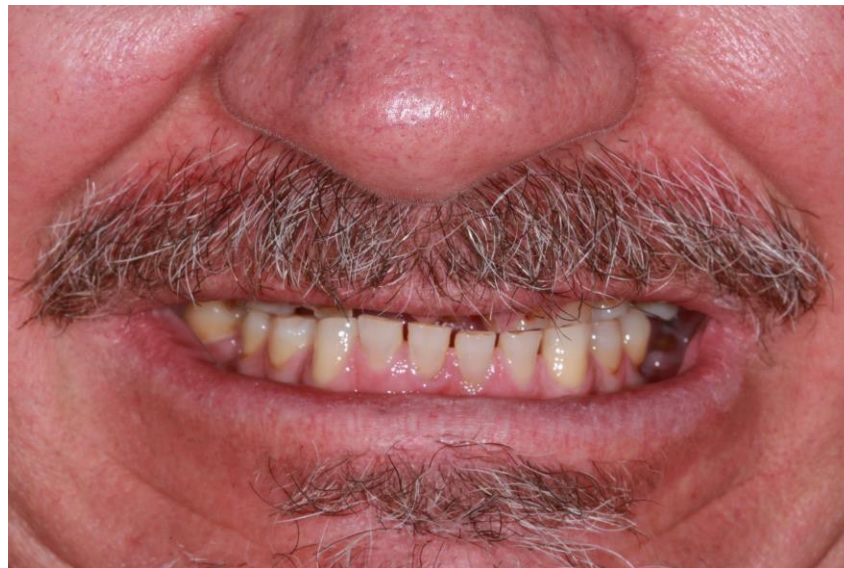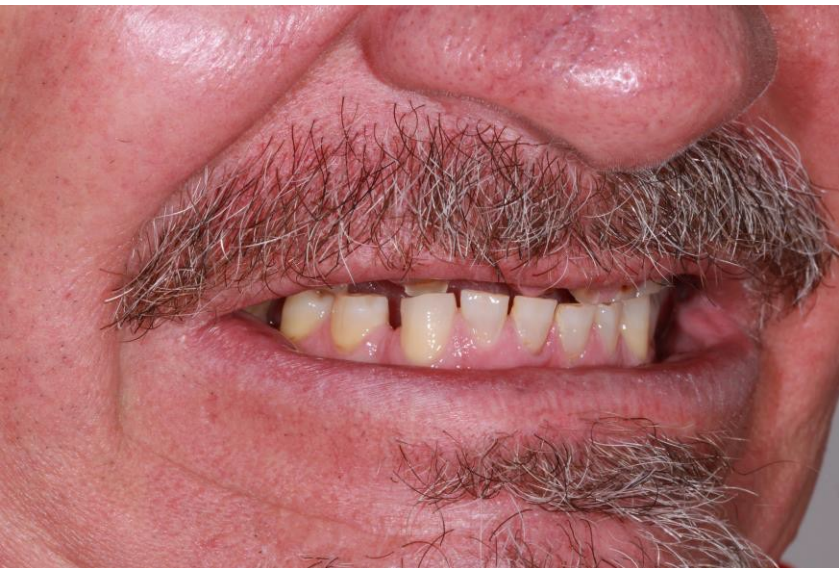*Dr. Jesús García de Blas y  
Dra. María Sánchez*

- \*Paciente Masculino
- \*Gran bruxista
- \*Gran pérdida de dimensión vertical
- \*Plan de tratamiento:  
Rehabilitación completa superior sobre implantes TSH by Phibo

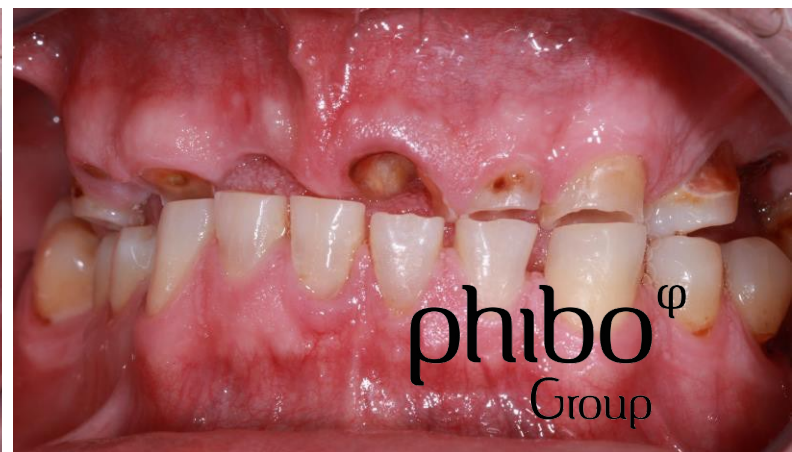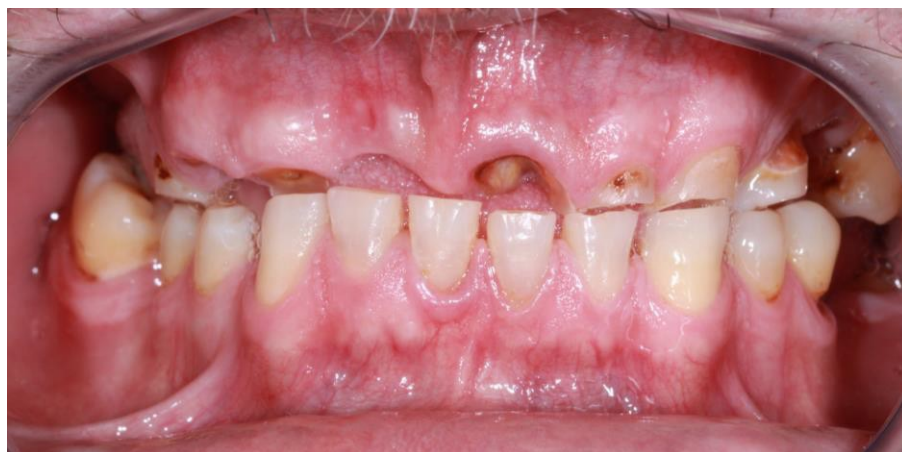Dr. Jesús García de Blas y  
Dra. María Sánchez

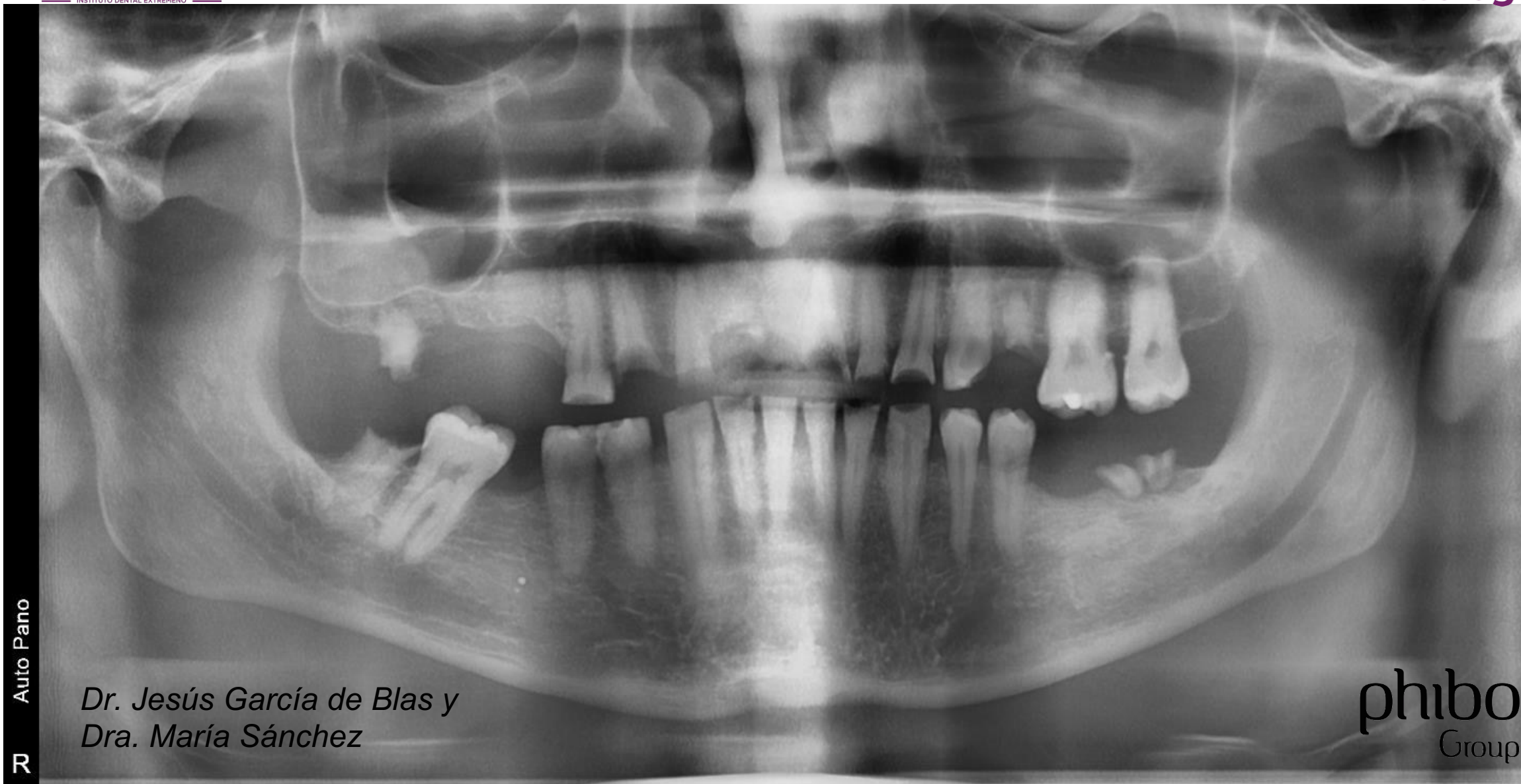






*Dr. Jesús García de Blas y  
Dra. María Sánchez*



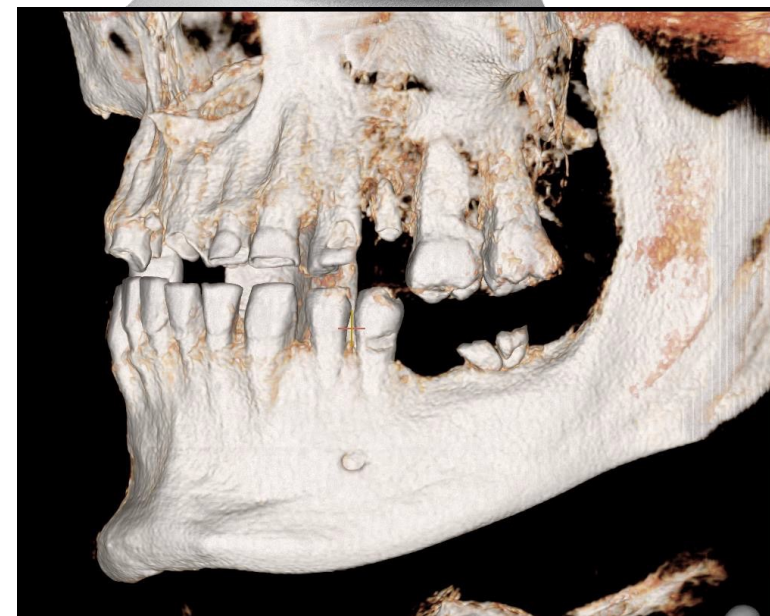
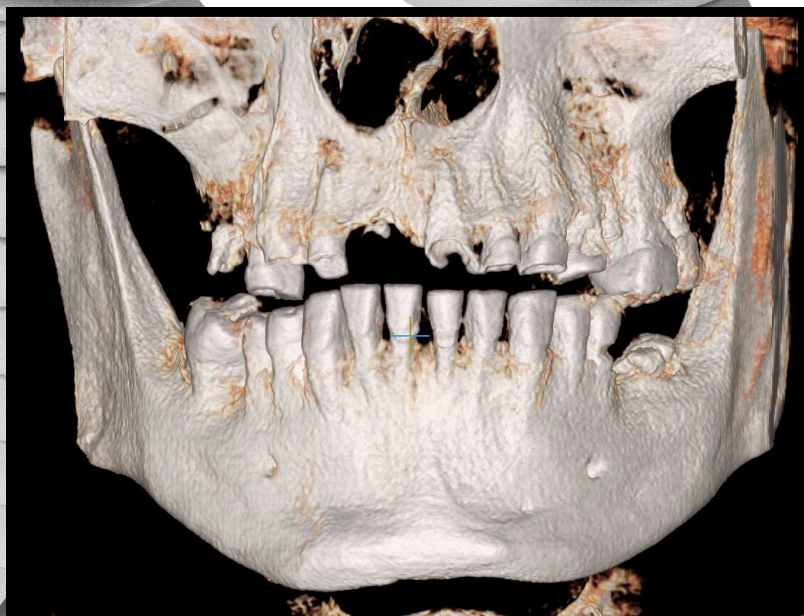
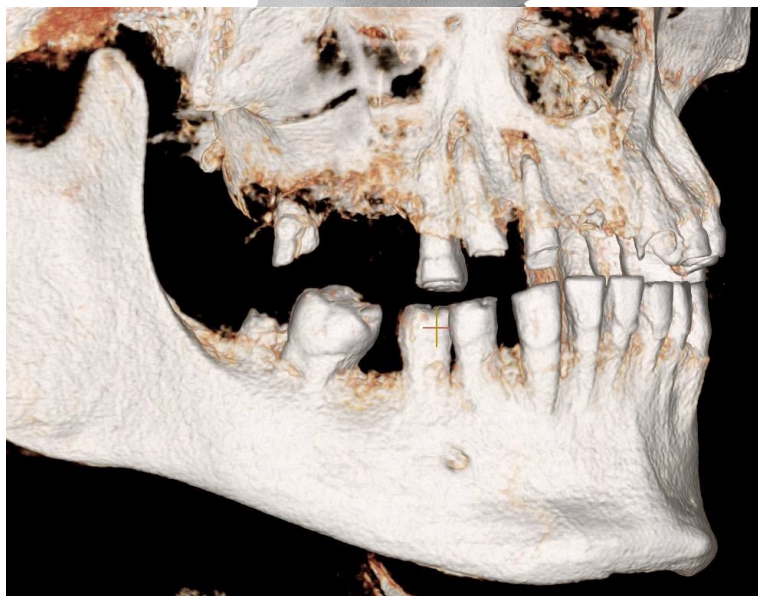Auto Pano

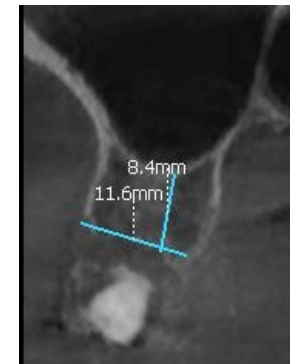
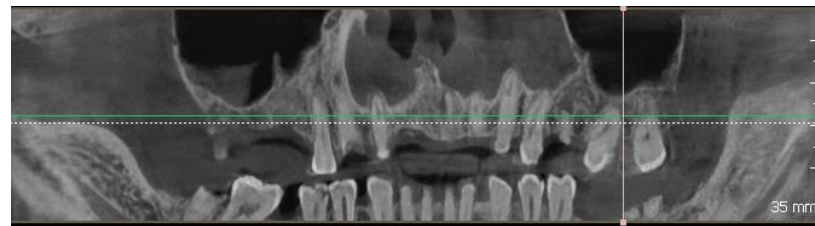
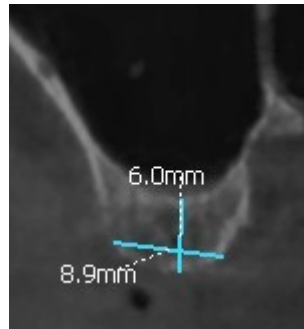
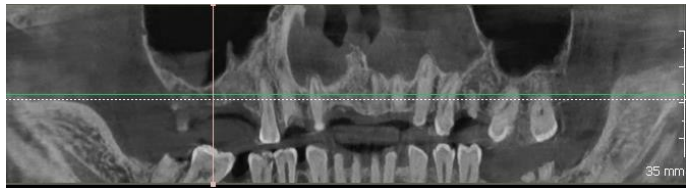
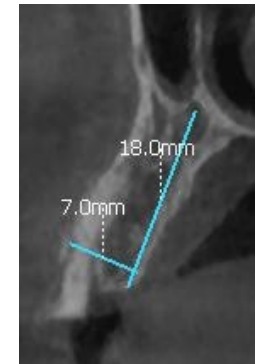
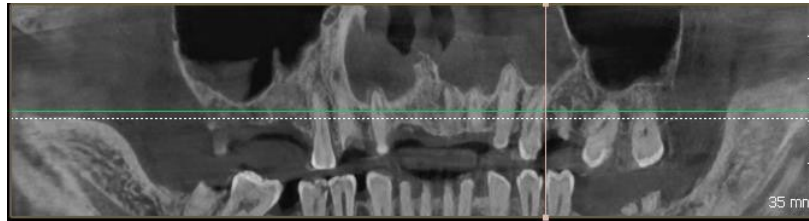
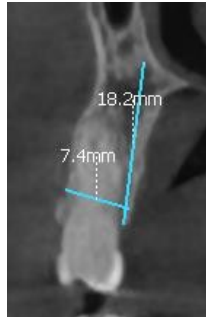
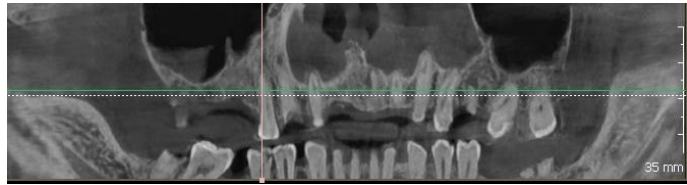

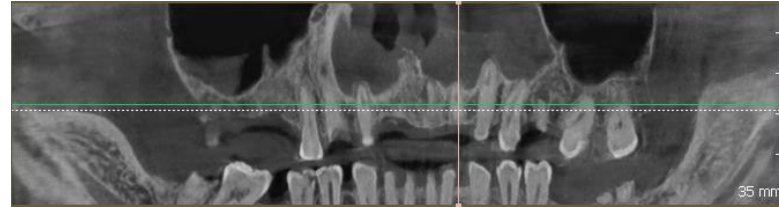

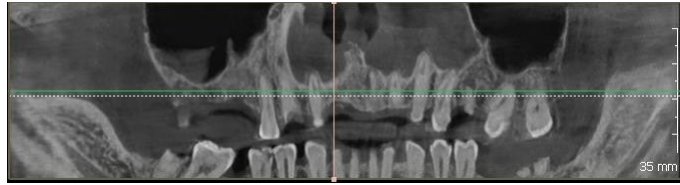


*Dr. Jesús García de Blas y  
Dra. María Sánchez*

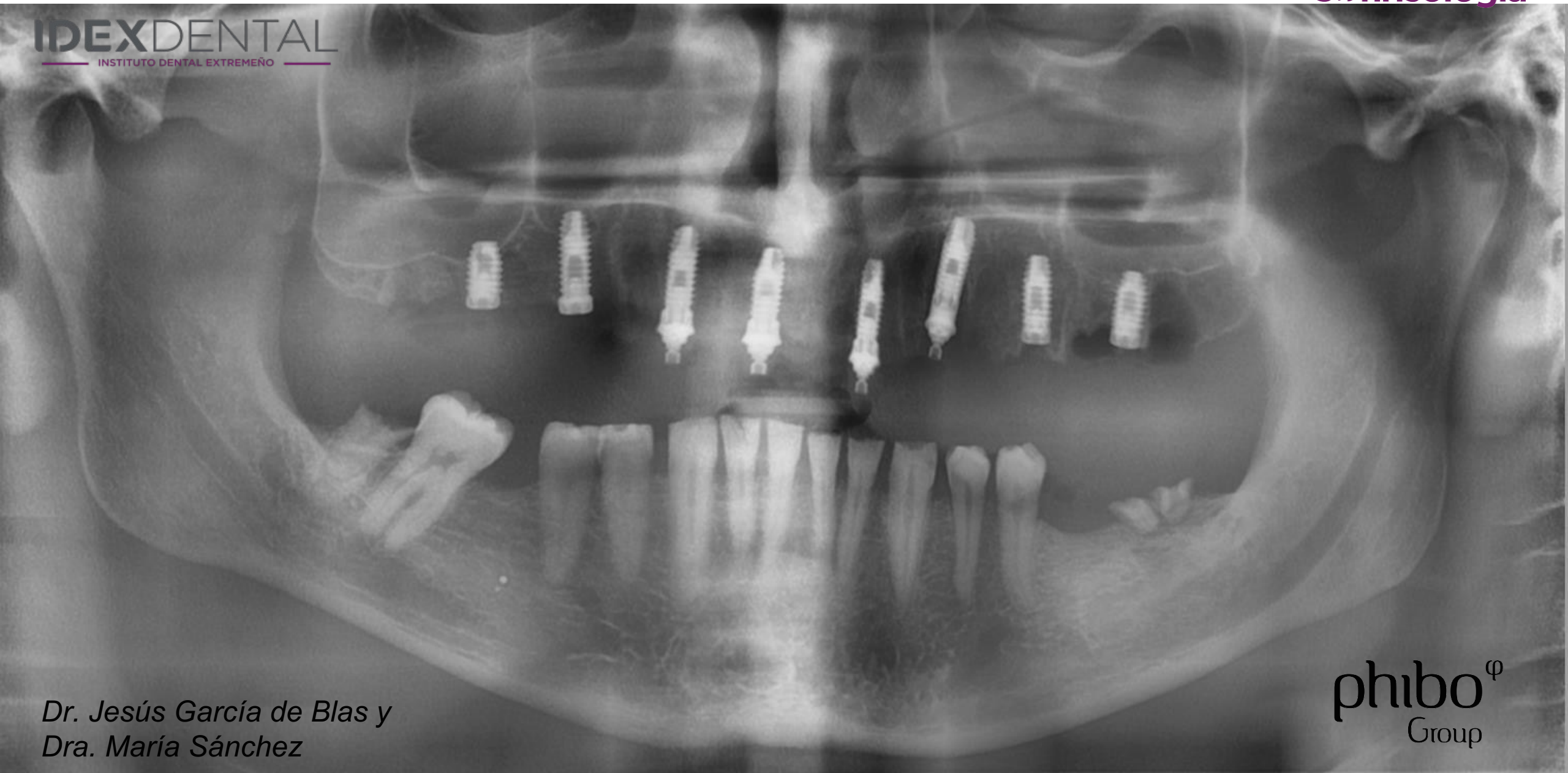**phibo**<sup>®</sup>  
Group



*Dr. Jesús García de Blas y  
Dra. María Sánchez*



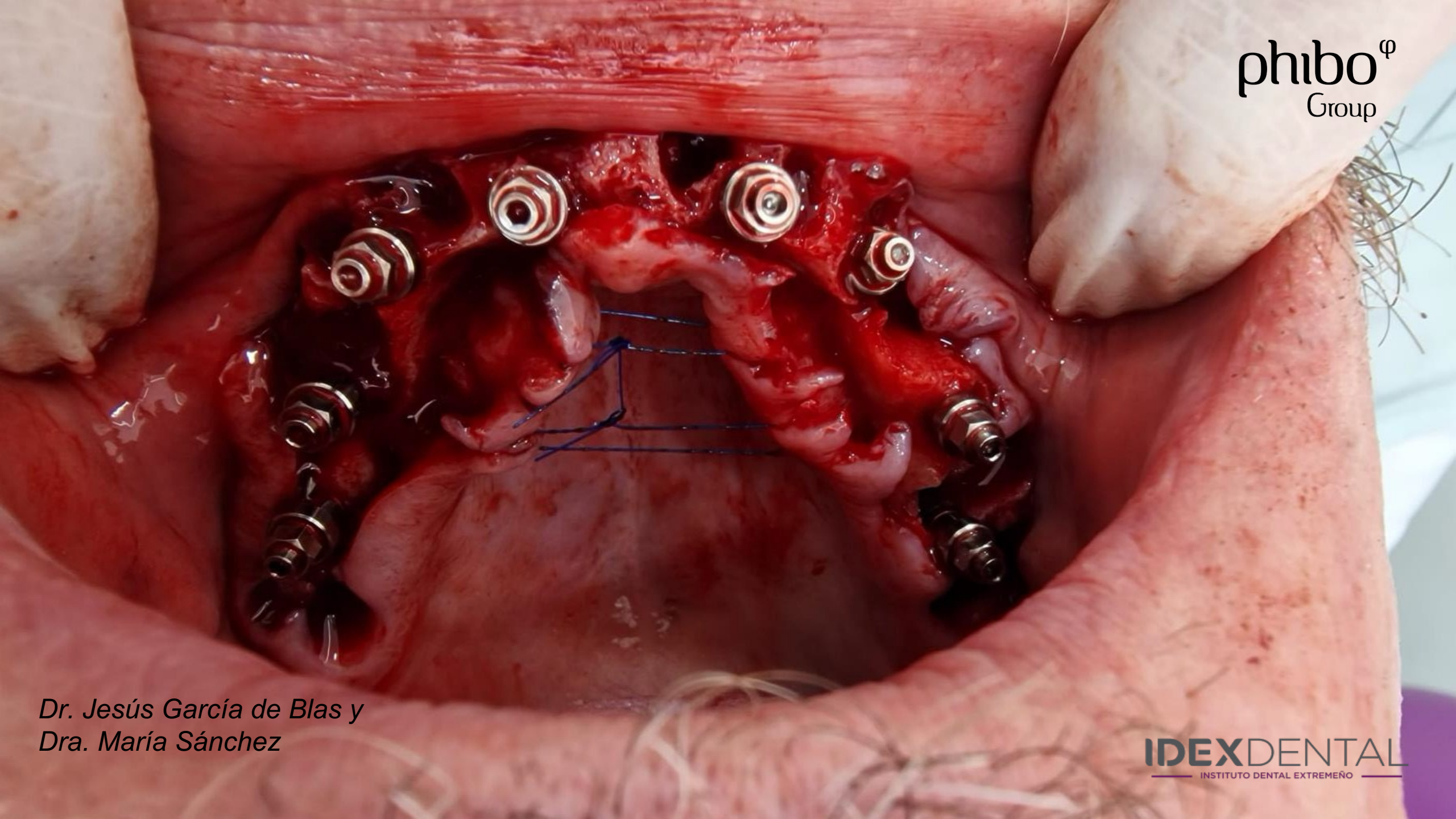
*Dr. Jesús García de Blas y  
Dra. María Sánchez*



*Dr. Jesús García de Blas y  
Dra. María Sánchez*

**phibo**<sup>φ</sup>  
Group



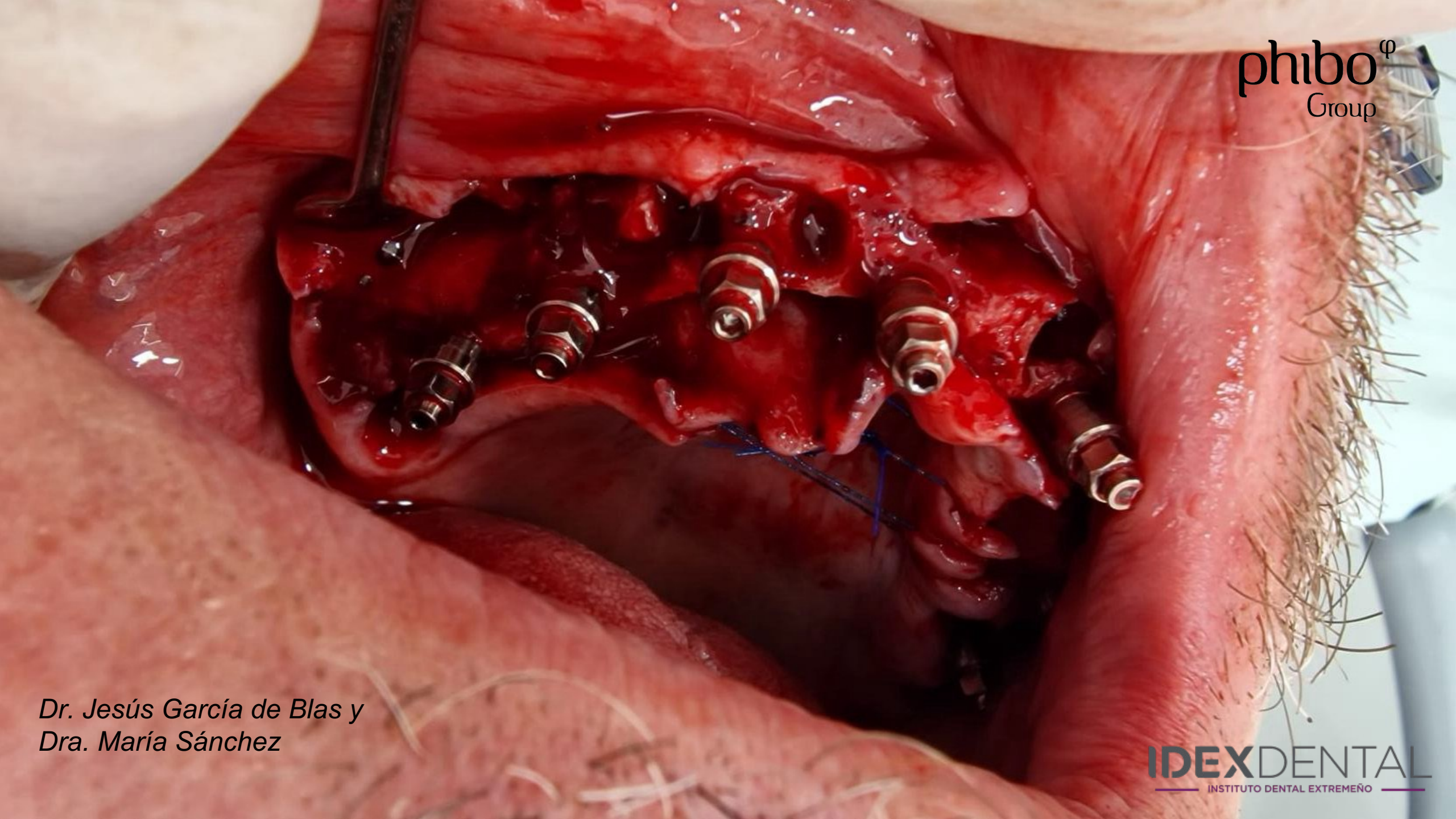


*Dr. Jesús García de Blas y  
Dra. María Sánchez*

phibo<sup>φ</sup>  
Group

*Dr. Jesús García de Blas y  
Dra. María Sánchez*

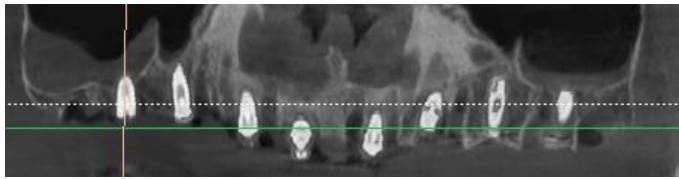
**IDEXDENTAL**  
INSTITUTO DENTAL EXTREMEÑO



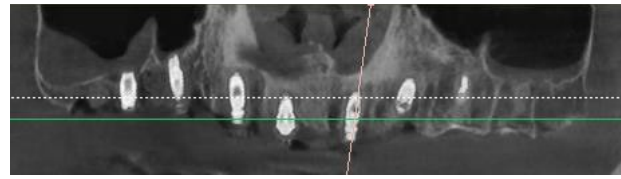
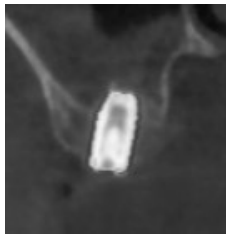*Dr. Jesús García de Blas y  
Dra. María Sánchez*

*Dr. Jesús García de Blas y  
Dra. María Sánchez*

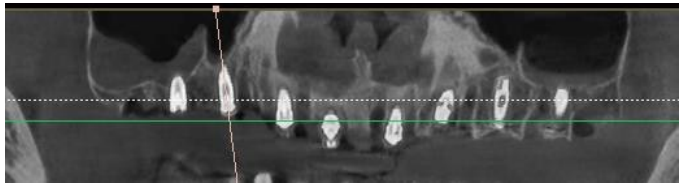
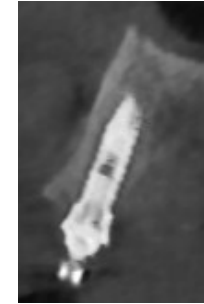*Dr. Jesús García de Blas y  
Dra. María Sánchez*



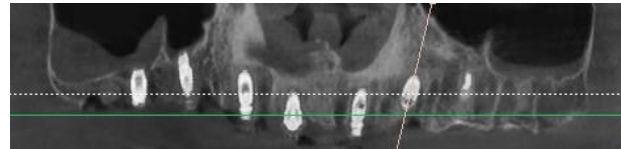
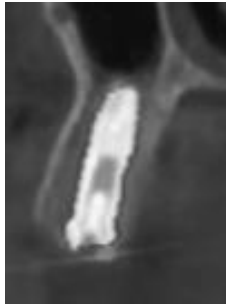IOI 17: s4X7 a 17N



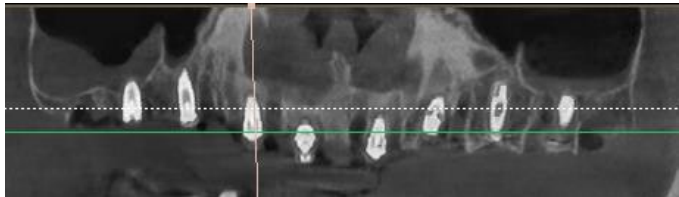
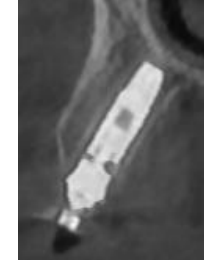
IOI 21: s3X11,5 a 20N



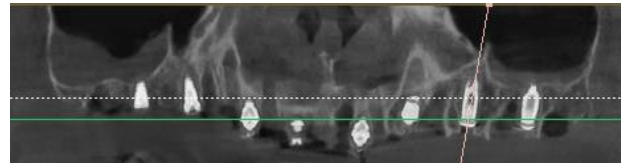
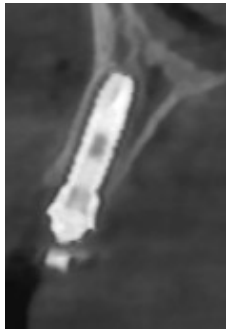IOI 15: s3X11,5 a 35N



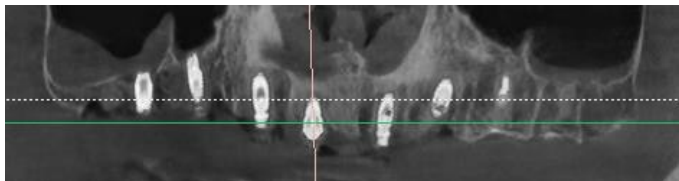
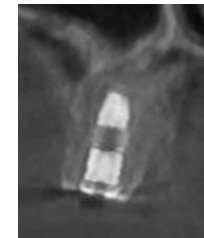IOI 23: s4X11,5 a 35N



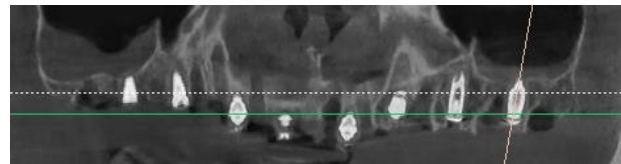
IOI 13: s3X11,5 a 35N



IOI 25: s4X10 a 10N



IOI 11: s3X10 a 35N



IOI 27: s4X8,5 a 8N



