



*Dr. Jesús García de Blas y  
Dra. María Sánchez*

- \*Paciente Femenina
- \*Edéntula total superior
- \*Gran pérdida de dimensión vertical y de tejido óseo en ambas zonas del maxilar.
- \*Plan de tratamiento:  
Rehabilitación completa superior sobre implantes TSH by Phibo

Dr. Jesús García de Blas y  
Dra. María Sánchez



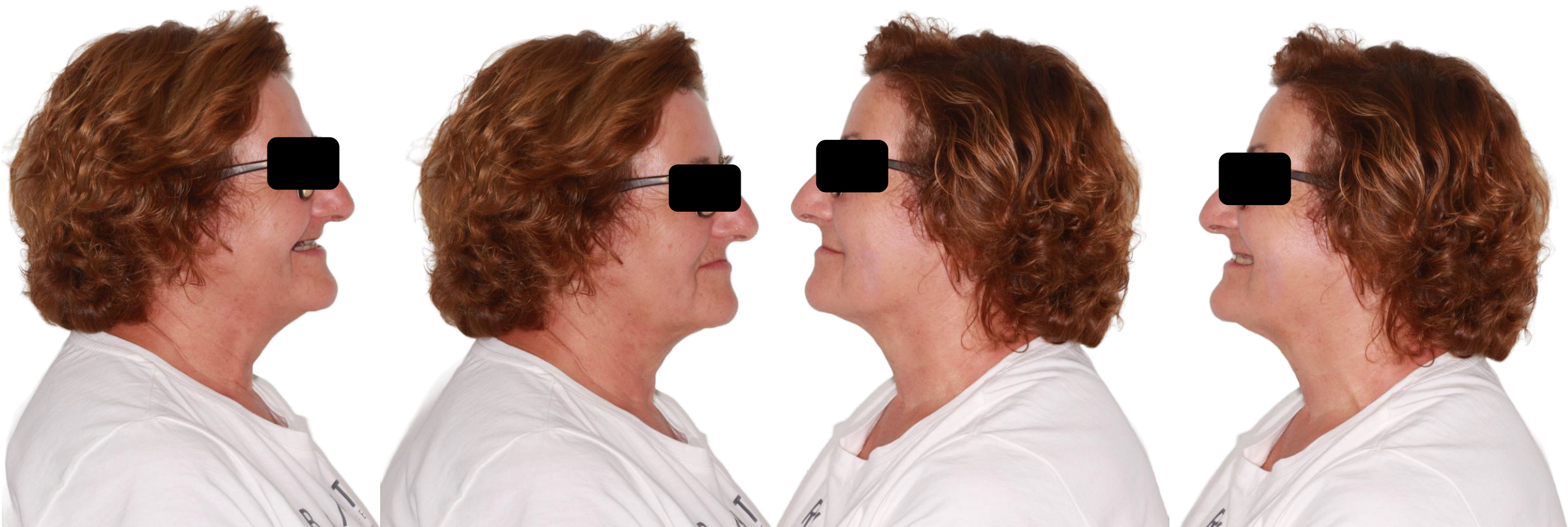## SITUACIÓN INICIAL DE LA PACIENTE:

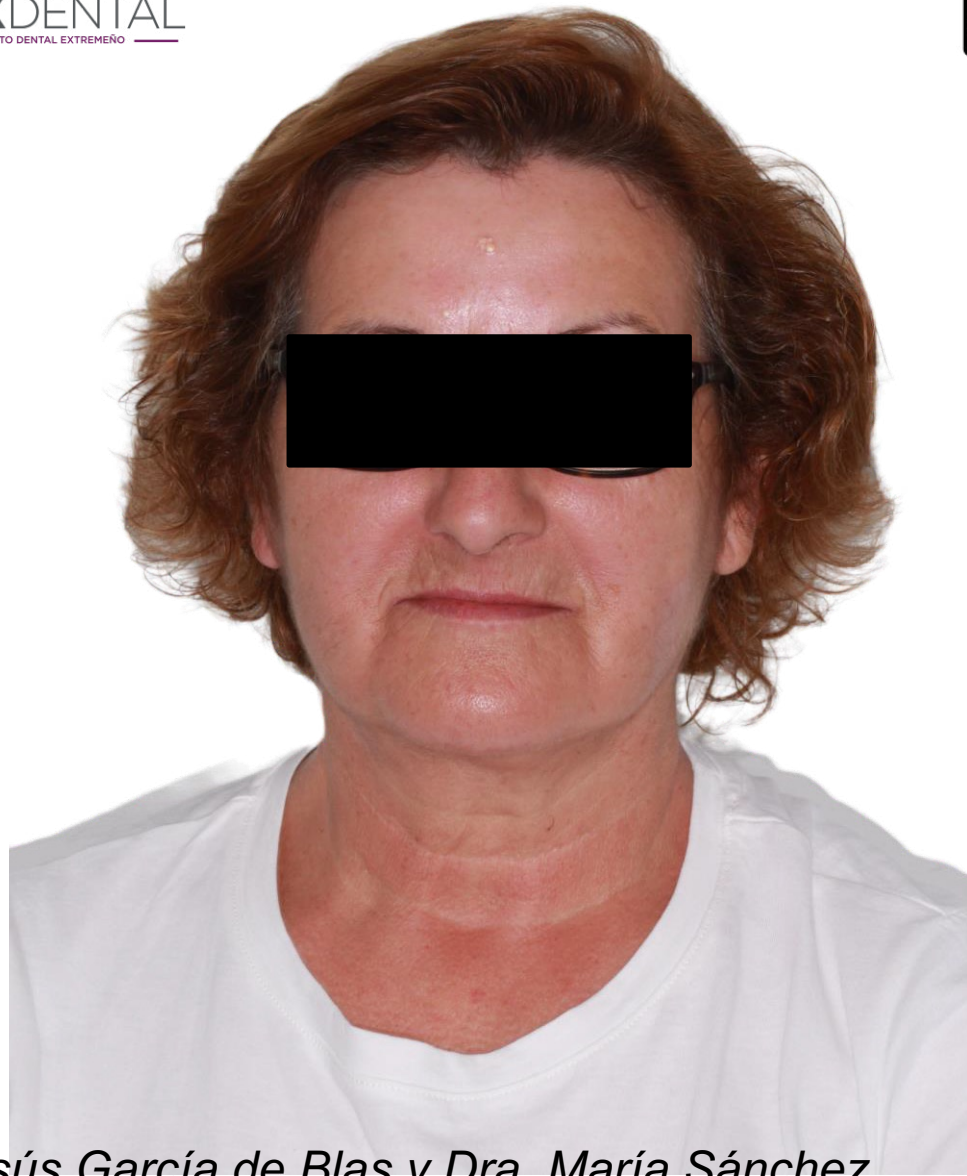- Paciente desdentada superior
- Portadora de prótesis removible
- Maxilar atrófico anterior (filo de cuchillo)
- Escasa altura posterior y hueso muy trabeculado
- Falta de soporte labial

## TRATAMIENTO:

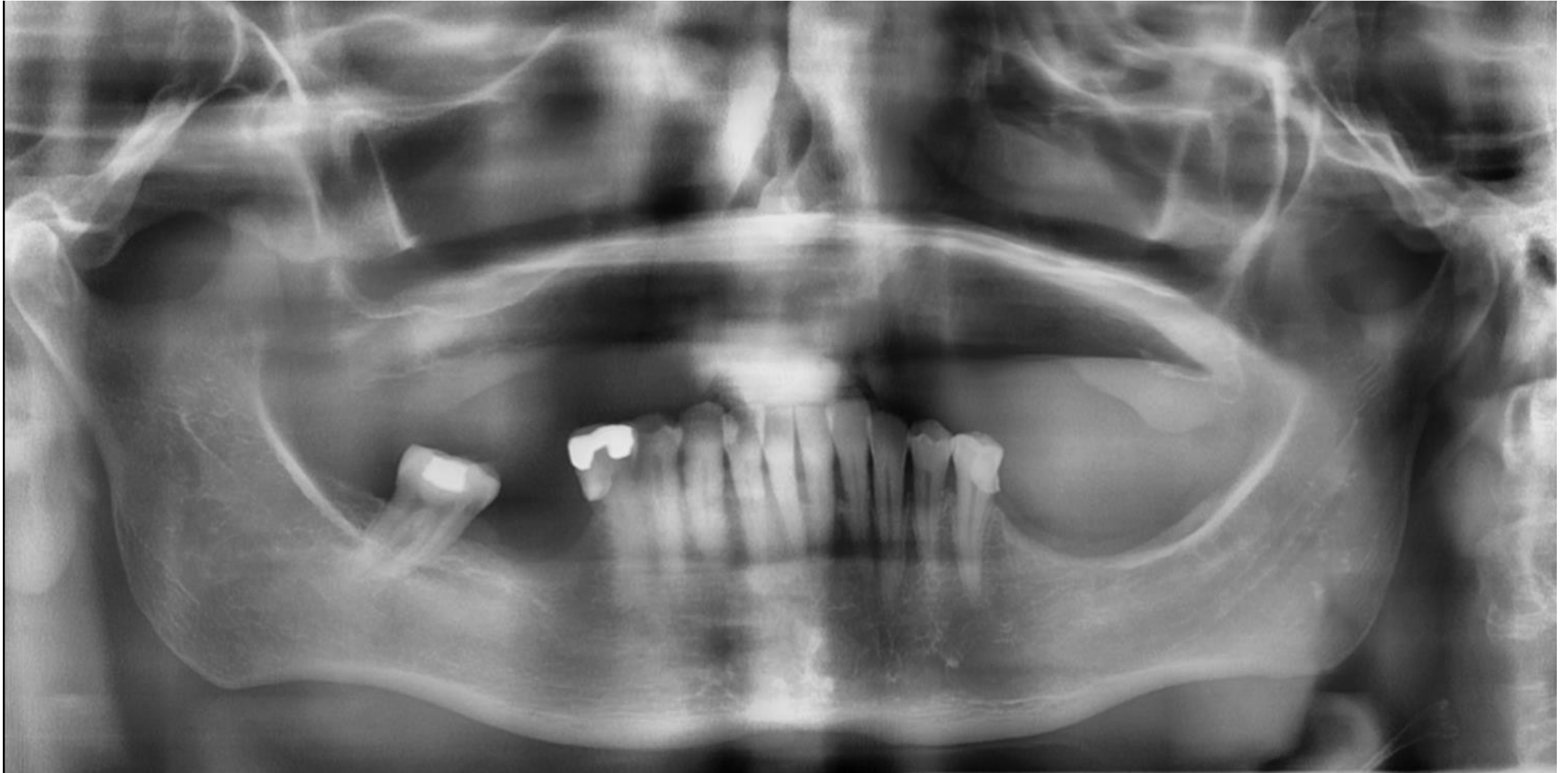- Colocación de implantes cortos en el sector posterior
  - Escaso fresado
  - Implantes de buena anchura
- Implante palatinizado anterior y anclado en fosa nasal
  - Implante estrecho
- Implantes angulados y palatinizados en zona de premolares
  - Implantes estrechos



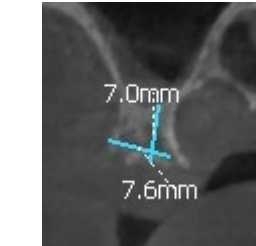
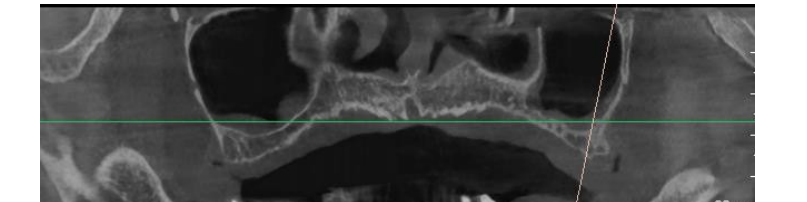
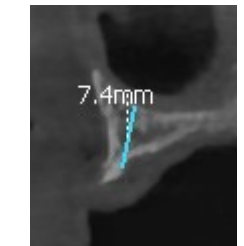
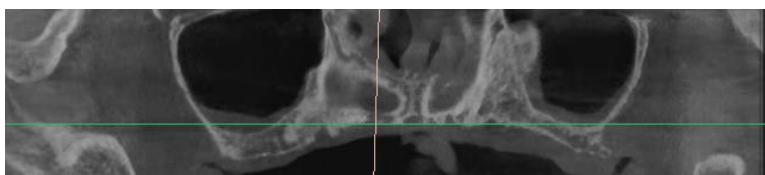
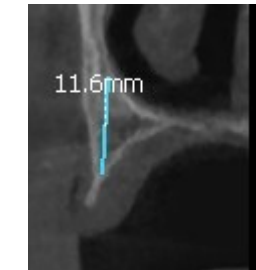
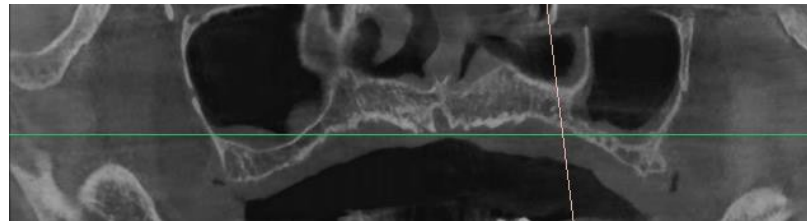
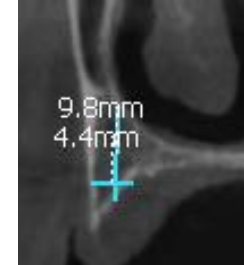
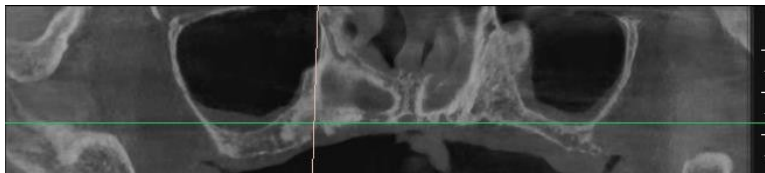
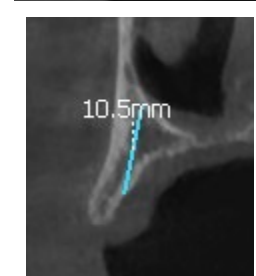
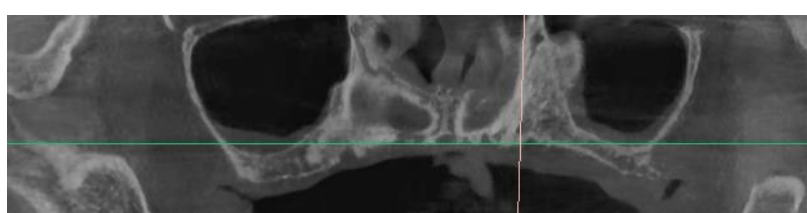
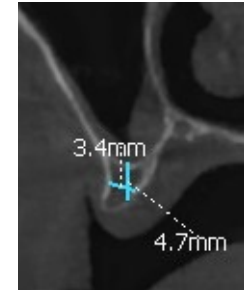
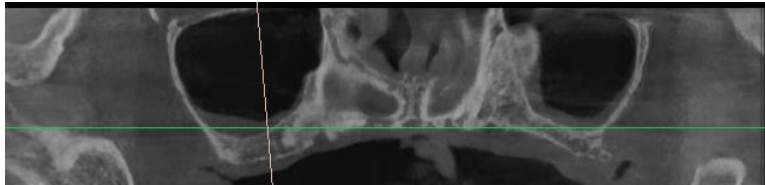
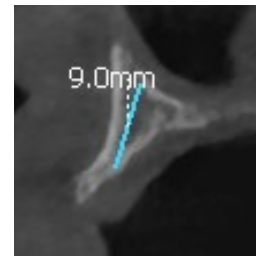
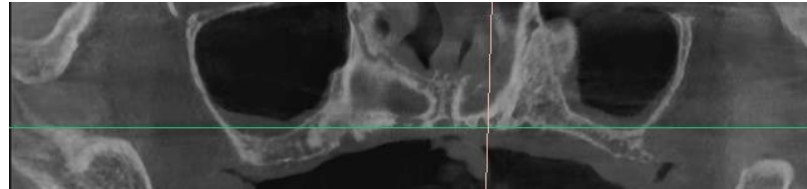
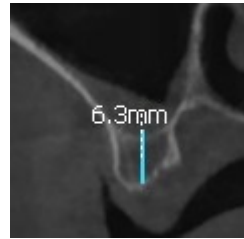
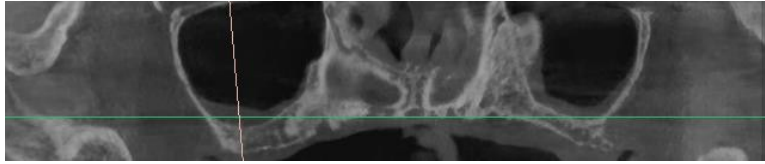


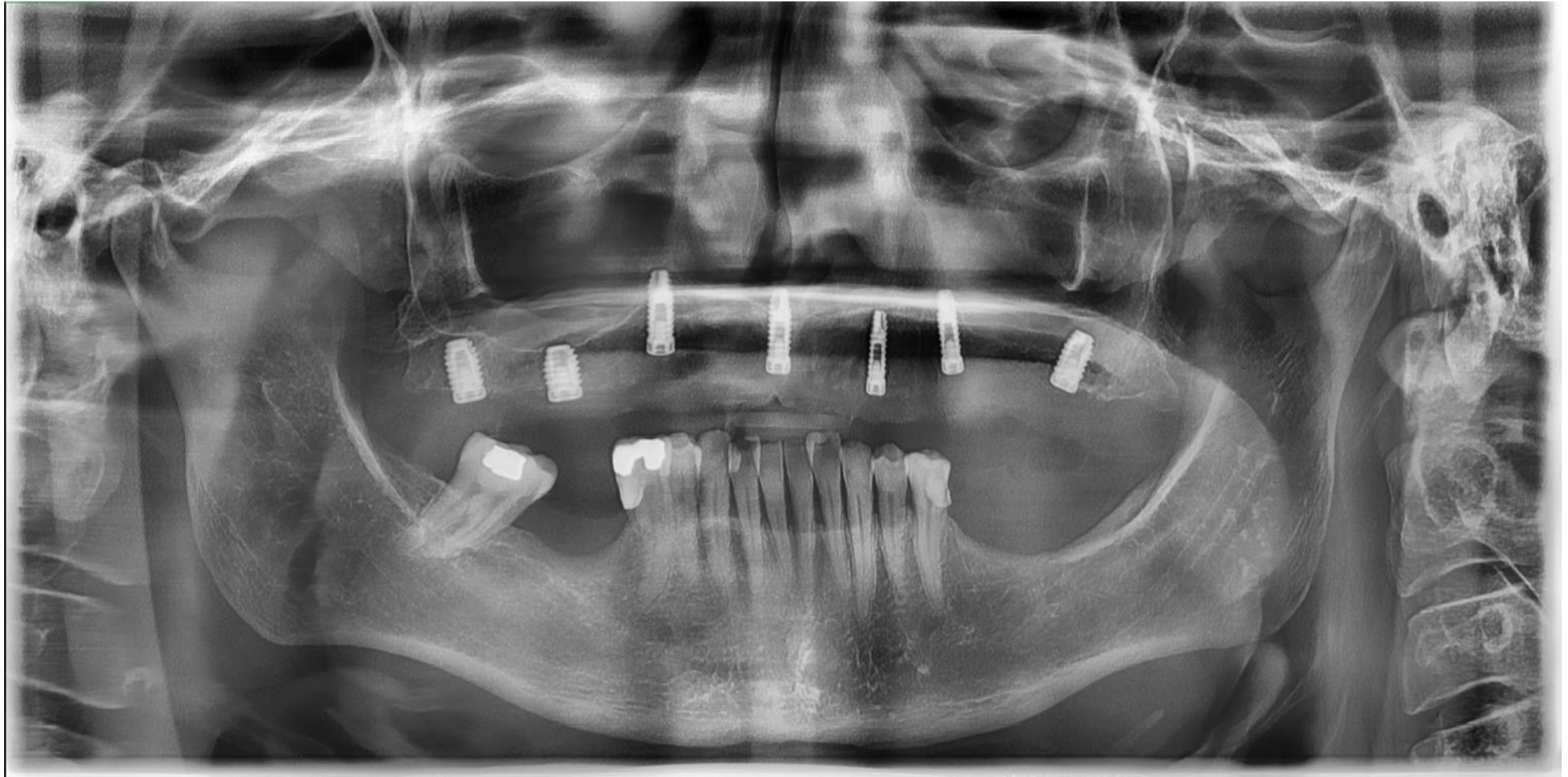


*Dr. Jesús García de Blas y Dra. María Sánchez*

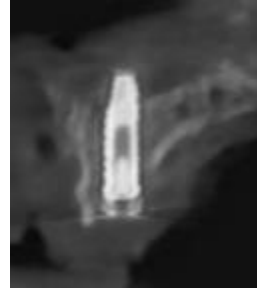
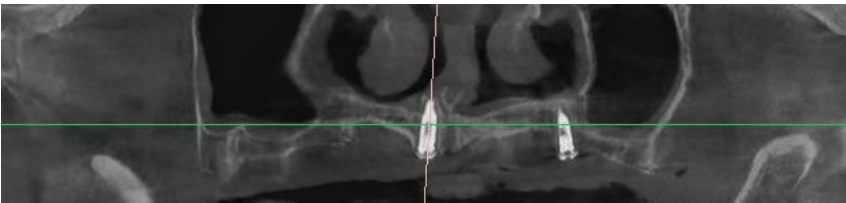
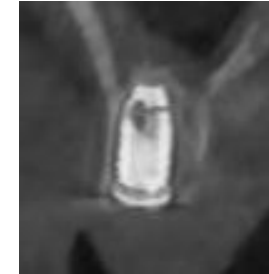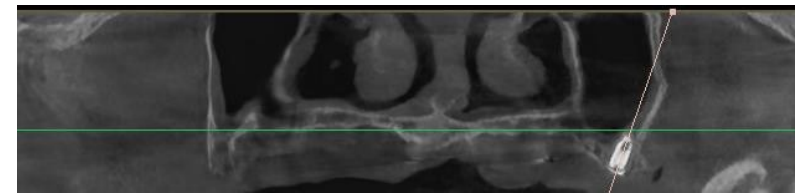
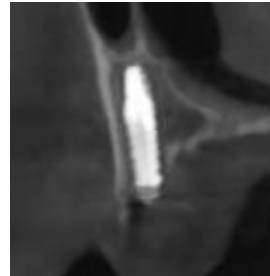
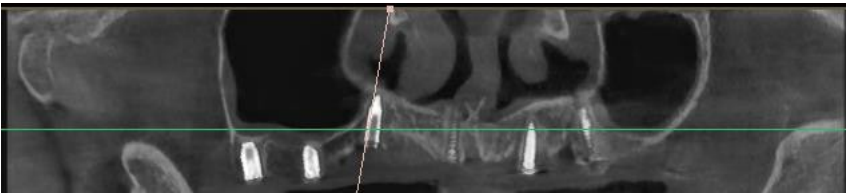
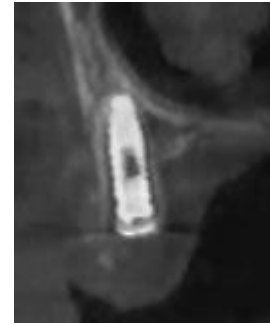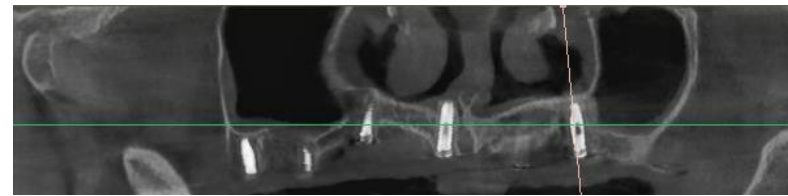
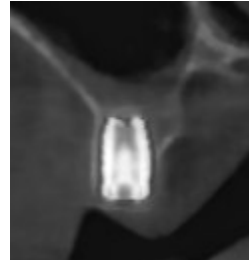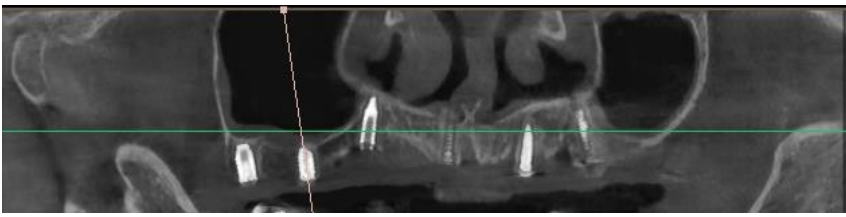
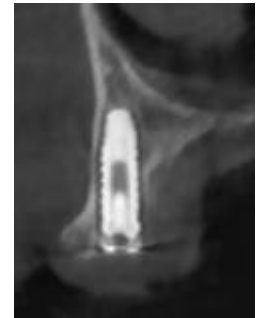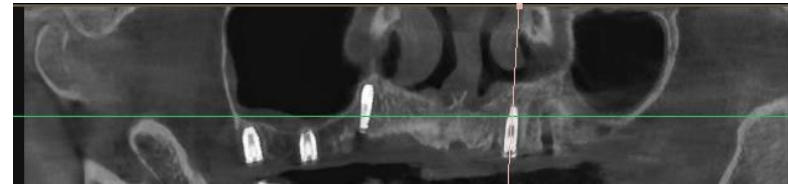
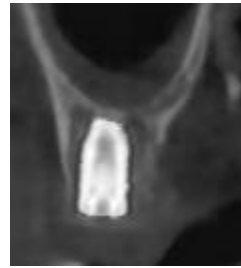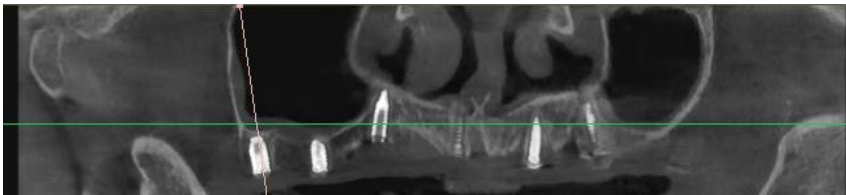


*Dr. Jesús García de Blas y Dra. María Sánchez*



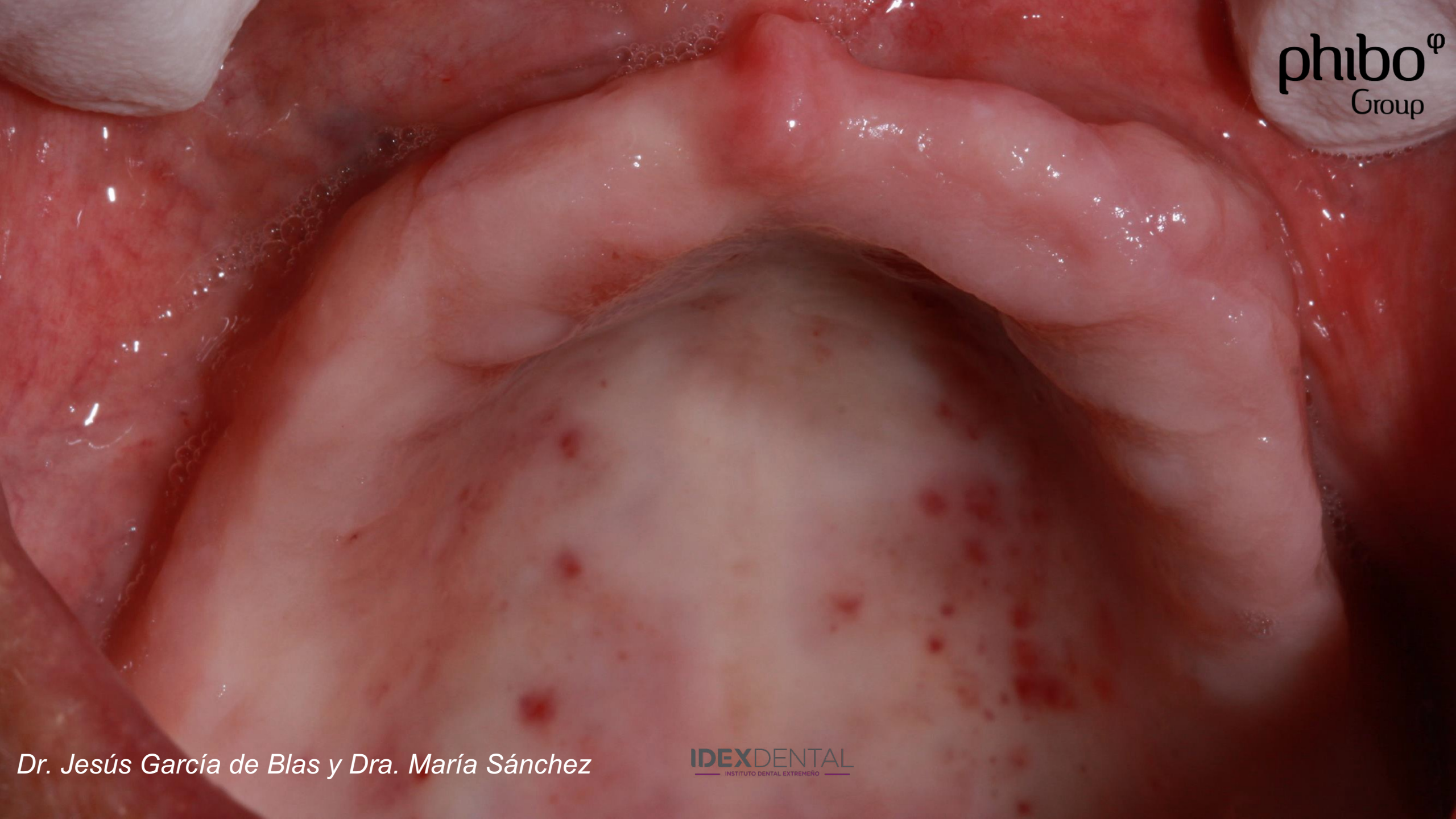


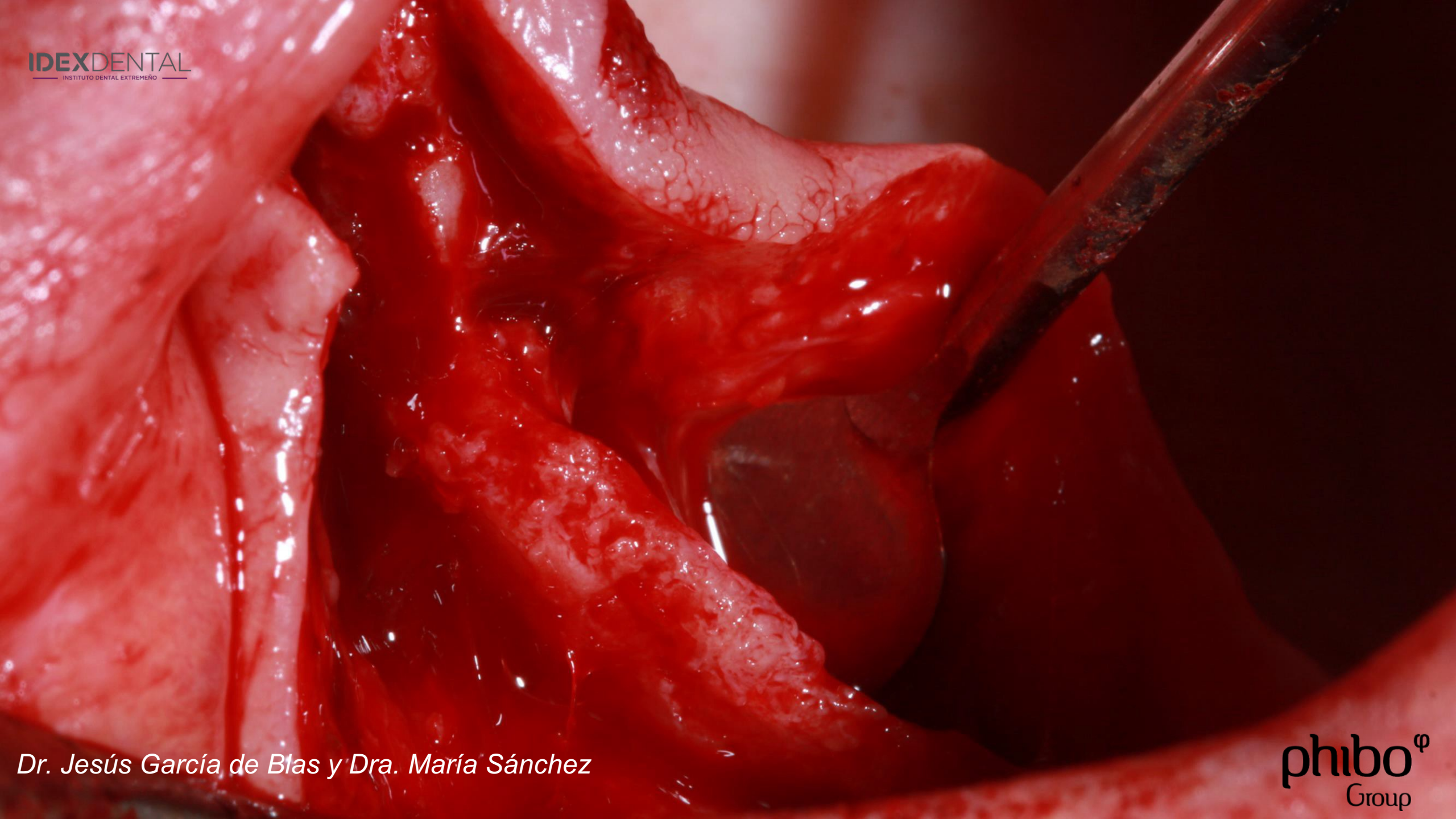


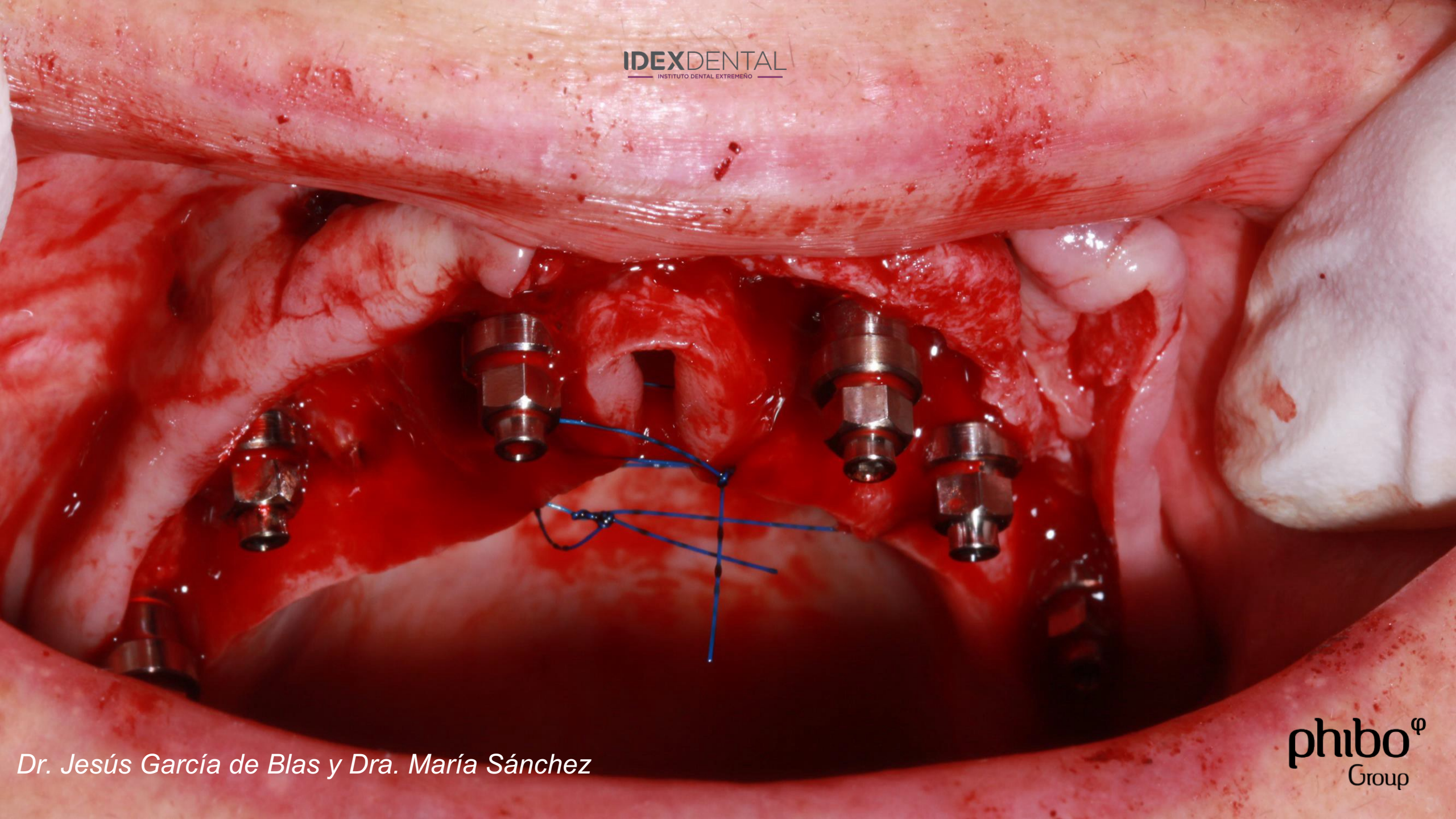
phibo<sup>φ</sup>  
Group

**IDEXDENTAL**  
INSTITUTO DENTAL EXTREMEÑO

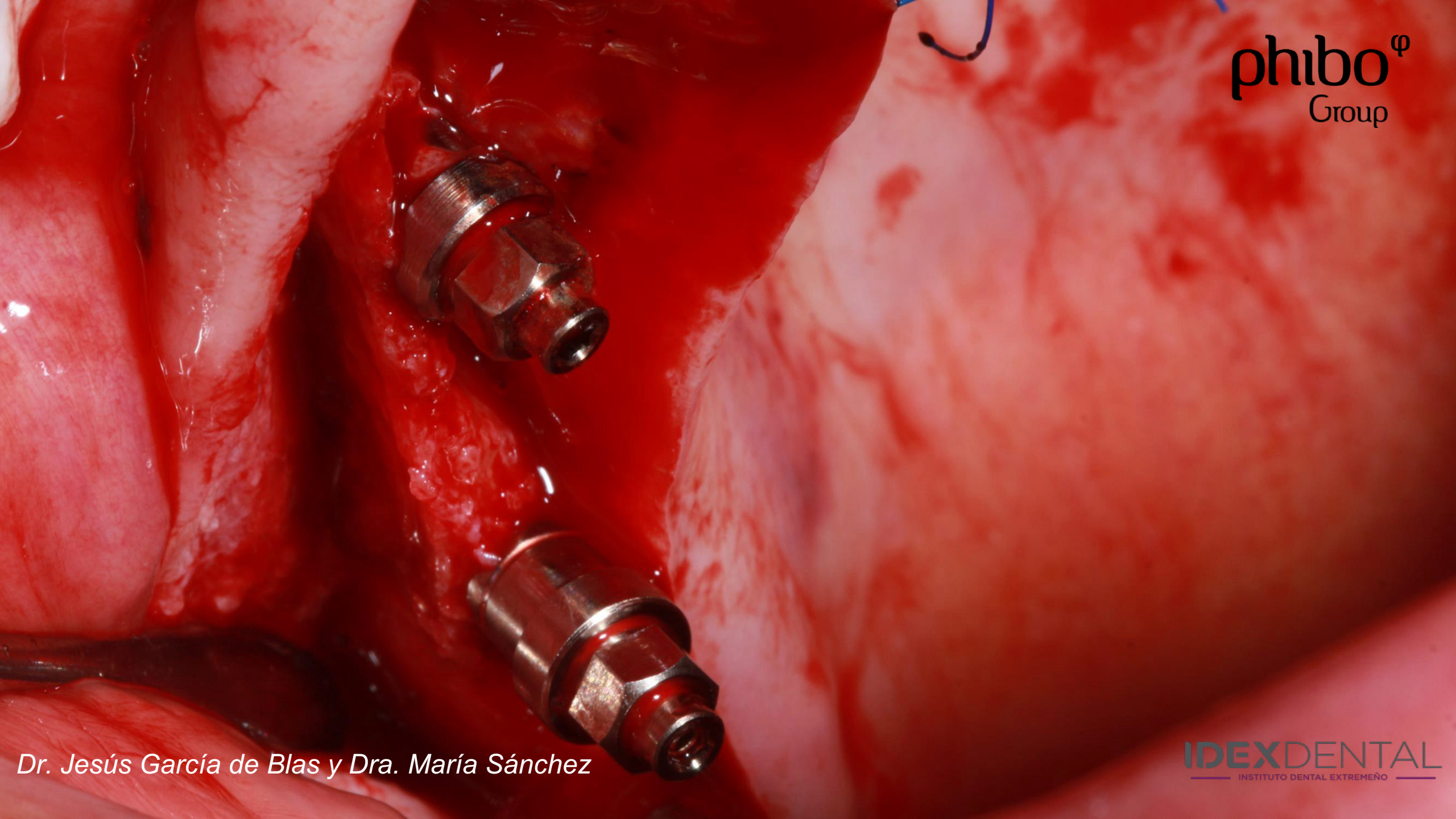


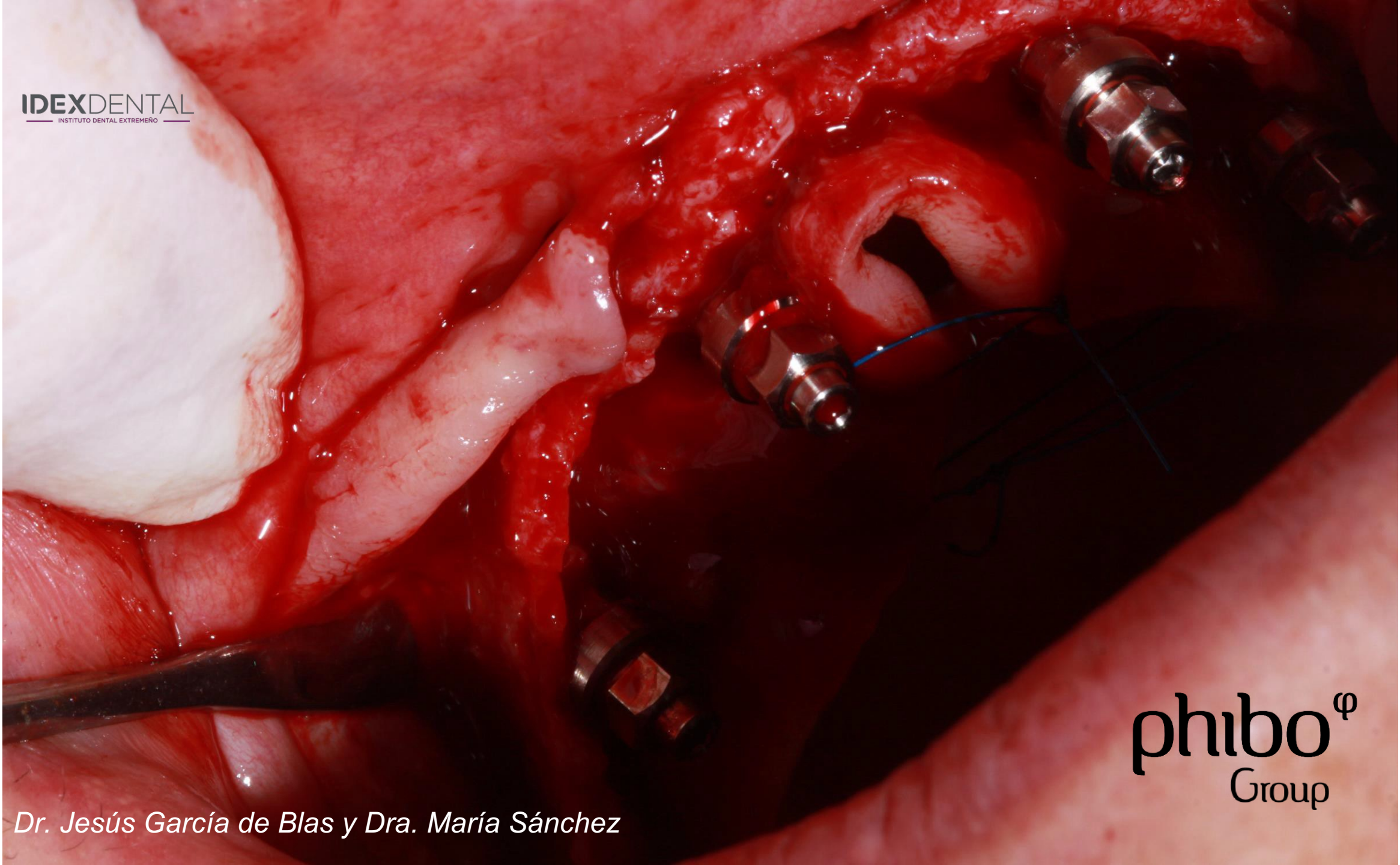


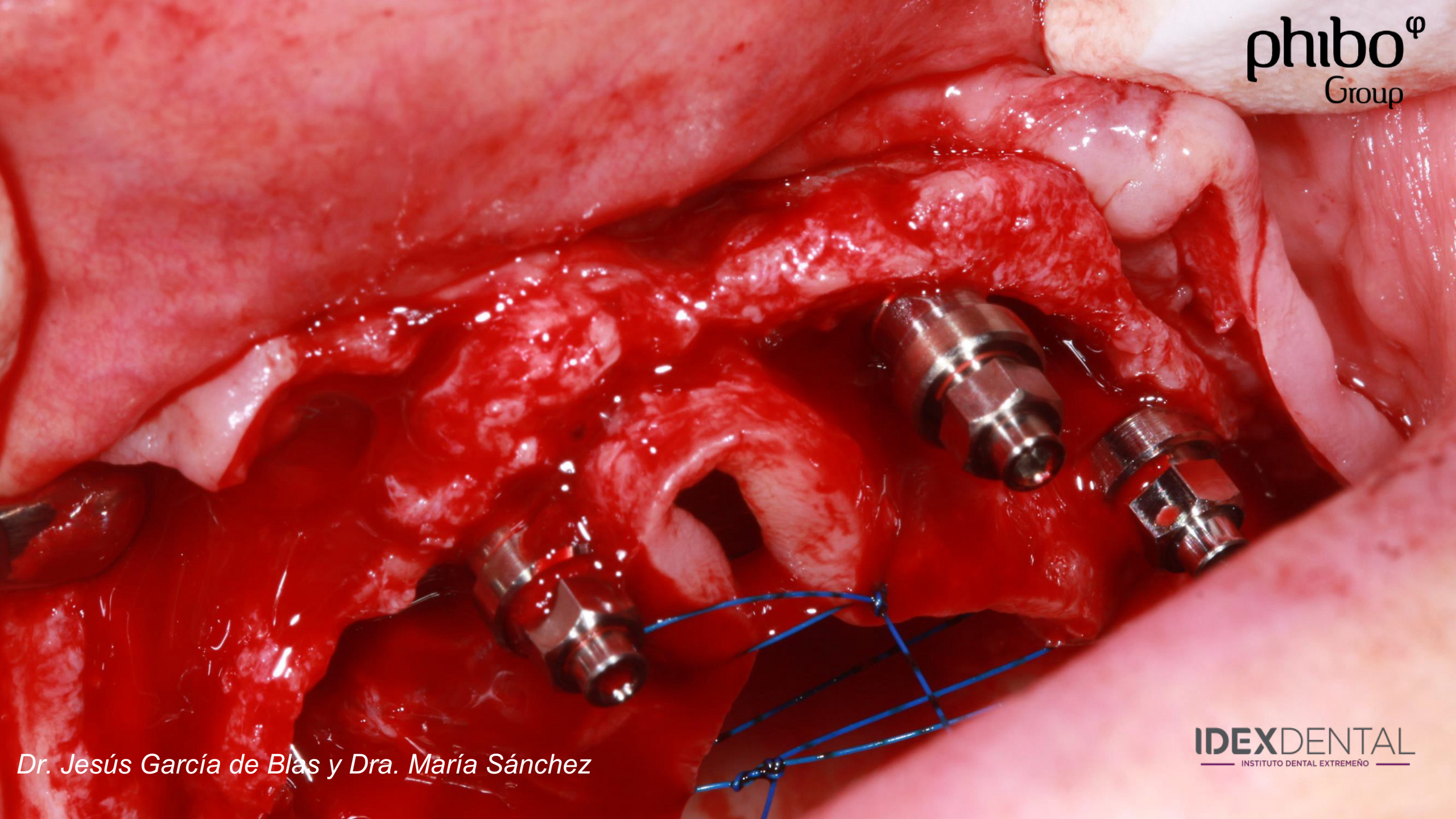
*Dr. Jesús García de Blas y Dra. María Sánchez*



*Dr. Jesús García de Blas y Dra. María Sánchez*









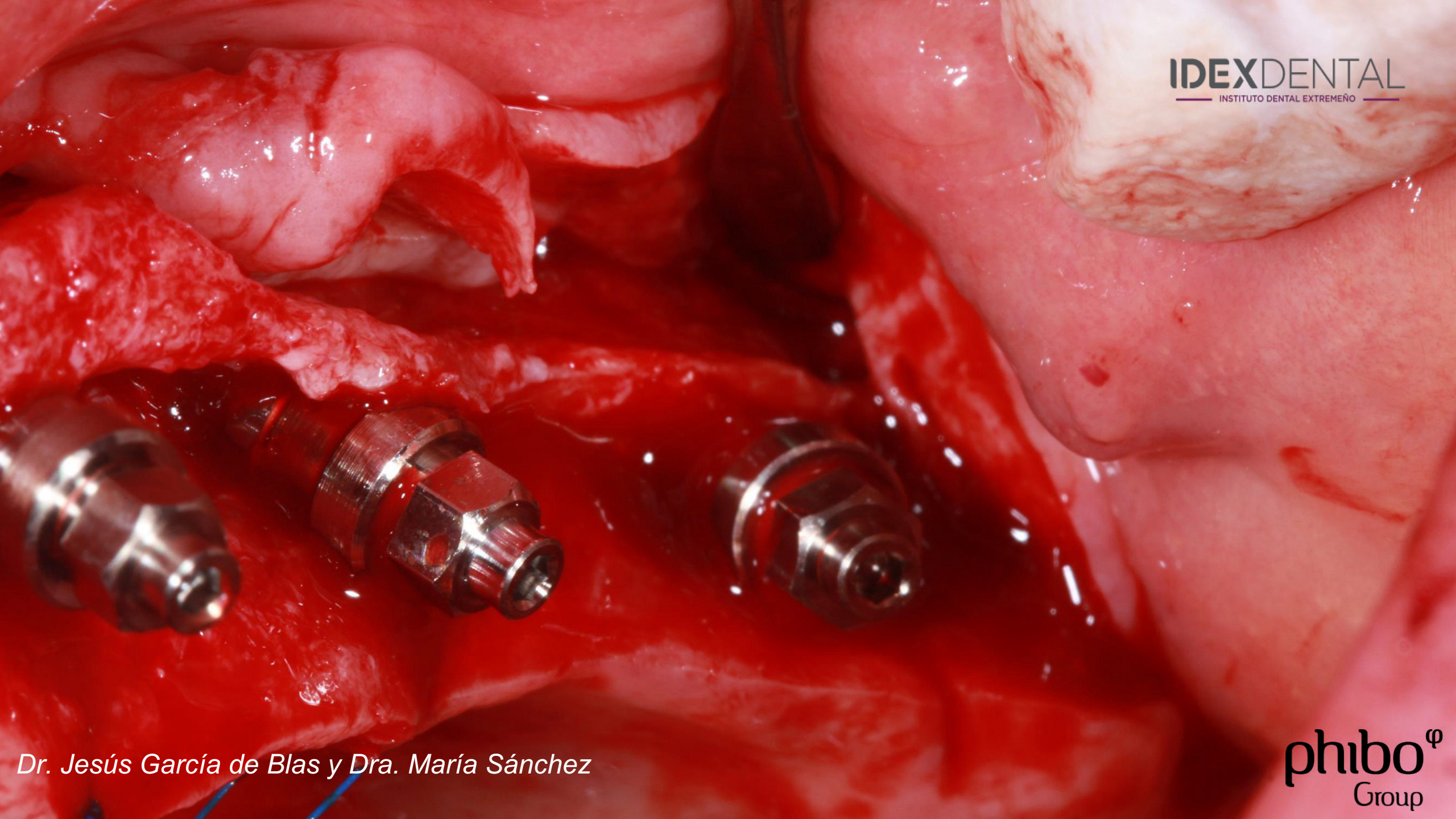


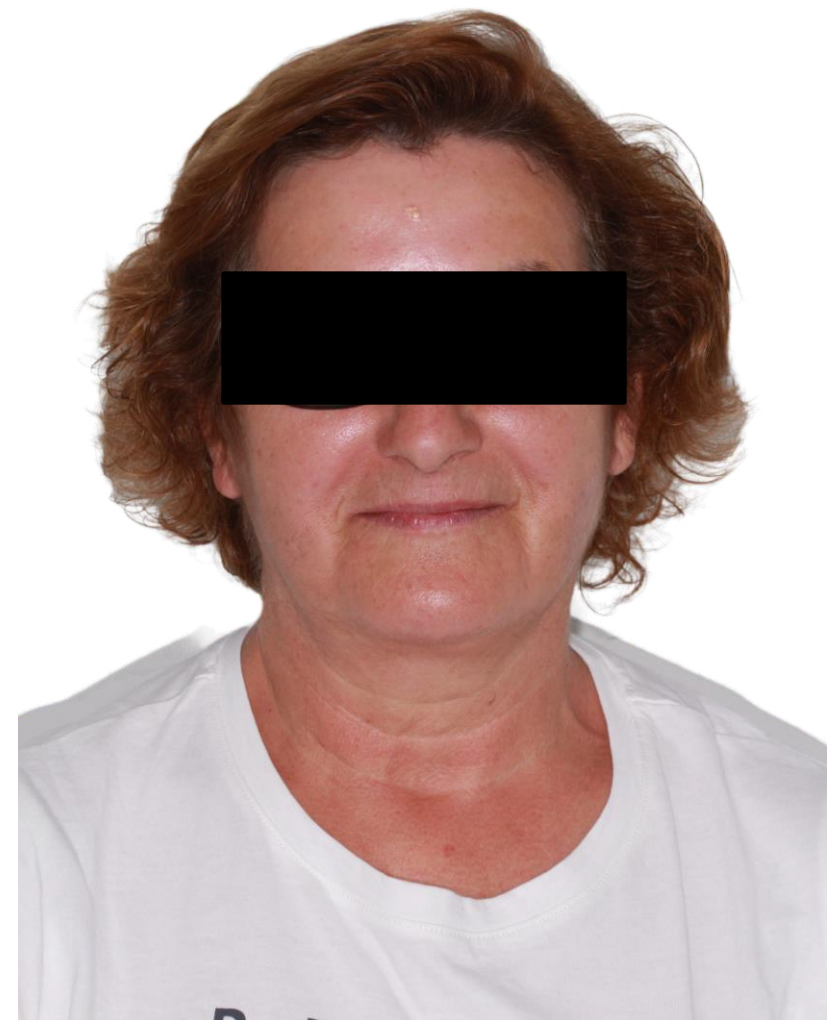A close-up photograph of a surgical site showing three dental implants. The implants are metallic and have a hexagonal top. They are embedded in a reddish, fleshy tissue. The surrounding tissue is moist and appears to be part of a surgical procedure. The implants are arranged in a slightly curved line.

phibo<sup>φ</sup>  
Group

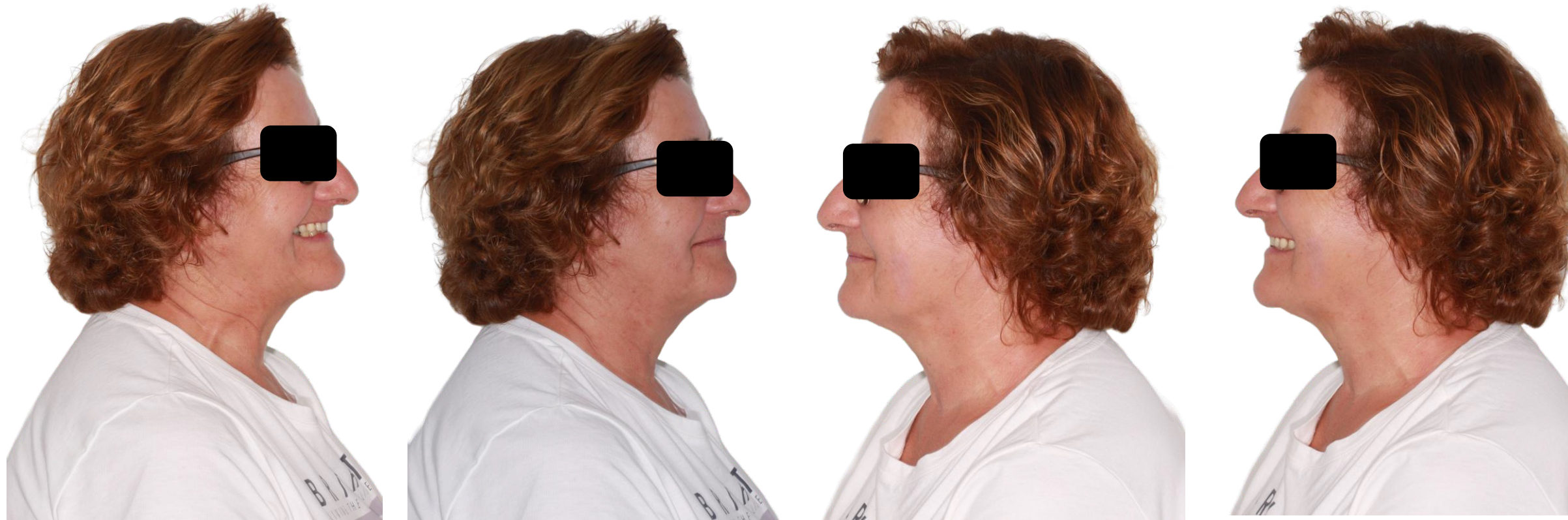**IDEXDENTAL**  
INSTITUTO DENTAL EXTREMEÑO

*Dr. Jesús García de Blas y Dra. María Sánchez*





Resultado Final



Resultado Final